



# Ruptured posterior circulation aneurysms: epidemiology, patterns of care, and outcomes from the Swiss SOS national registry

Rodolfo Maduri<sup>1</sup> · Daniele Staronni<sup>1</sup> · Alda Rocca<sup>1</sup> · David Bervini<sup>2</sup> · Daniel Walter Zumofen<sup>3,4</sup> · Martin Nikolaus Stienen<sup>5</sup> · Bawarjan Schatlo<sup>6</sup> · Christian Fung<sup>7</sup> · Thomas Robert<sup>8</sup> · Martin A. Seule<sup>9</sup> · Jan-Karl Burkhardt<sup>5,10</sup> · Nicolai Maldaner<sup>5</sup> · Michel Rothlisberger<sup>3</sup> · Kristine A. Blackham<sup>4</sup> · Serge Marbacher<sup>11</sup> · Donato D'Alonzo<sup>11</sup> · Luca Remonda<sup>12</sup> · Paolo Machi<sup>13</sup> · Jan Gralla<sup>14</sup> · Philippe Bijlenga<sup>15</sup> · Guillaume Saliou<sup>16</sup> · Pierluigi Ballabeni<sup>17,18</sup> · Marc Levivier<sup>1,18</sup> · Mahmoud Messerer<sup>1,18</sup> · Roy Thomas Daniel<sup>1,18</sup> · Swiss SOS Group

Received: 11 December 2018 / Accepted: 12 January 2019 / Published online: 25 January 2019  
© Springer-Verlag GmbH Austria, part of Springer Nature 2019, corrected publication 2019

## Abstract

**Background** The treatment of ruptured posterior circulation aneurysms remains challenging despite progresses in the endovascular and neurosurgical techniques.

**Objective** To provide epidemiological characterization of subjects presenting with ruptured posterior circulation aneurysms in Switzerland and thereby assessing the treatment patterns and neurological outcomes.

**Methods** This is a retrospective analysis of the Swiss SOS registry for patients with aneurysmal subarachnoid hemorrhage. Patients were divided in 3 groups (upper, lower, and middle third) according to aneurysm location. Clinical, radiological, and treatment-related variables were identified and their impact on the neurological outcome was determined.

**Results** From 2009 to 2014, we included 264 patients with ruptured posterior circulation aneurysms. Endovascular occlusion was the most common treatment in all 3 groups (72% in the upper third, 68% in the middle third, and 58.8% in the lower third). Surgical treatment was performed in 11.3%. Favorable outcome (mRS  $\leq 3$ ) was found in 56% at discharge and 65.7% at 1 year. No significant difference in the neurological outcome were found among the three groups, in terms of mRS at discharge ( $p = 0.20$ ) and at 1 year ( $p = 0.18$ ). High WFNS grade, high Fisher grade at presentation, and rebleeding before aneurysm occlusion ( $p = 0.001$ ) were all correlated with the risk of unfavorable neurological outcome (or death) at discharge and at 1 year.

**Conclusions** In this study, endovascular occlusion was the principal treatment, with a favorable outcome for two-thirds of patients at discharge and at long term. These results are similar to high volume neurovascular centers worldwide, reflecting the importance of centralized care at specialized neurovascular centers.

**Keywords** Aneurysmal subarachnoid hemorrhage · Posterior circulation · Intracranial aneurysms · Ruptured aneurysms · Endovascular procedures · Intracranial vasospasm · Hydrocephalus

## Introduction

### Background and rationale

Aneurysmal subarachnoid hemorrhage (aSAH) accounts for about 5% of strokes [5, 30]. The reported incidence of aSAH

variates according to the region from 3 to 20 cases for 100,000 person-years [5].

Ruptured aneurysms may be located in the anterior part of the circle of Willis (internal carotid artery, middle cerebral artery, anterior cerebral artery, and anterior communicating complex) or in the posterior circulation (vertebrobasilar system and posterior cerebral artery) [2, 29]. Posterior circulation aneurysms account for 10–15% of aSAH, whereas the anterior circulation lesions represent the large majority [14]. Endovascular occlusion for ruptured posterior circulation aneurysms is accomplished in up to 85% of cases, while surgical treatment is indicated in specific cases based on aneurysm morphology

---

This article is part of the Topical Collection on *Vascular Neurosurgery - Aneurysm*

✉ Rodolfo Maduri  
Rodolfo.maduri@gmail.com

Extended author information available on the last page of the article

and location and the presence of large hematomas requiring evacuation [1, 35, 36].

Surgical occlusion of ruptured posterior circulation aneurysms remains challenging due to the rarity of these aneurysms combined with the lesser familiarity and the more difficult surgical exposure compared to the anterior circulation [14, 44]. Furthermore, due to the rarity of these aneurysms, detailed clinical outcome data are lacking [44].

## Objective

By reviewing the data from the nationwide database of the Swiss Study On Aneurysmal Subarachnoid Hemorrhage (Swiss SOS; <http://www.swiss-sos.ch>) [33], this study aims to provide an epidemiological characterization of subjects presenting with a posterior circulation aSAH in Switzerland and thereby assessing the treatment patterns and neurological outcomes.

## Methods

### Study design

We performed a retrospective analysis of anonymized data from the Swiss SOS registry, a nationwide cohort study for aSAH (<https://clinicaltrials.gov/ct2/show/NCT03245866>).

Ethics committee approval was obtained from 7 participating centers (under the supervision of the Geneva Ethics Committee Board no. 11-233R, NAC 11-085R). Pre-specified uniform definitions were used for recorded variables, and data were entered into a Secutrial™ platform (InterActive Systems GmbH, Berlin, Germany), at the time of patient discharge and follow-up. Swiss SOS study registry and methods of collection of data and analysis have been published previously [3]: [24, 31, 37, 48].

### Patients and variables

After retrospective chart review of the Swiss SOS registry on aSAH, all patients with ruptured posterior circulation aneurysms were included.

Patient characteristics at presentation in terms of age, sex, World Federation of neurosurgical Society (WFNS) grading scale at admission (before resuscitation) [28], Fisher grade [6], and epilepsy and aneurysm morphology were collected. Treatment variables were the aneurysm occlusion modality (endovascular, surgical, combined, or none), the placement of an external ventricular drain (EVD) or ventriculoperitoneal (VP) shunt, and endovascular treatment for vasospasm. For subgroup analysis, aneurysm locations were subdivided into 3 groups based on common anatomic compartments according to the classification described by Sanai

et al. [32](Fig. 1), namely, (1) upper third (basilar artery tip, posterior cerebral artery (PCA), superior cerebellar artery (SCA), post-communicating segment of the PCA (P2)), (2) the middle third (basilar trunk and anterior-inferior cerebellar artery (AICA)), and (3) the lower third (posterior-inferior cerebellar artery (PICA), vertebro-basilar junction (VA-BA junction), vertebral artery (VA)).

Treatment and interventions were analyzed for these three groups.

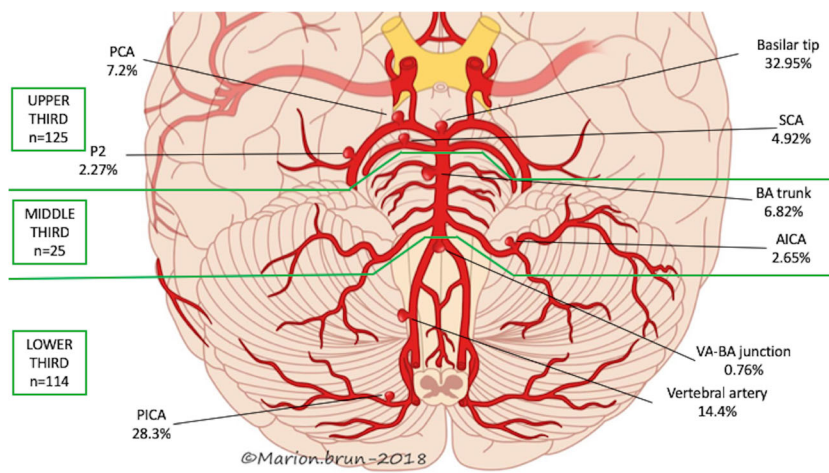
The complications considered in our analysis were the following:

- Rebleeding before aneurysm occlusion: a sudden clinical deterioration with signs of increased hemorrhage on consecutive computed tomography (CT) scans, or if no CT scan was obtained, sudden clinical deterioration suspected to be the cause of rebleeding with fresh blood in the ventricular drain. In addition, acute clinical deterioration (e.g., acute neurological deterioration, bradycardia, or sudden blood hypertension) at the emergency department or before imaging were considered as rebleeding. Acute clinical deterioration before admission was not taken into account [43];
- Hydrocephalus defined as the dilatation of the cerebral ventricles requiring cerebrospinal fluid (CSF) diversion (EVD or VP shunt placement);
- Symptomatic vasospasm requiring endovascular treatment;
- Clinical deterioration attributable to delayed cerebral ischemia was defined as the development of new focal neurological signs and/or deterioration in level of consciousness, lasting for more than 1 h attributed to delayed cerebral ischemia (DCI) [42];
- Cerebral infarction attributable to DCI and not related to the primary bleed or treatment [42].

The modified Rankin score (mRS) [41] at discharge (Fig. 2) and at 1-year follow-up (Fig. 3) was used to assess the clinical outcome for the 3 groups. For the correlation analysis between clinical and treatment variables and the neurological outcome, the mRS was dichotomized as follows: (1) favorable outcome (mRS ≤ 3), (2) unfavorable (mRS 4–5), or (3) dead (6). A survival analysis was also performed for the three groups.

### Statistical method

We applied Fisher's exact tests to assess the associations between aneurysm location and the categorical outcomes and Kruskal-Wallis tests to assess the associations between aneurysm location and the modified Rankin score. Survival time (months) was estimated by means of the Kaplan-Meier function, whereby data were censored for patients alive at the last



**Fig. 1** Artist drawing showing distribution of aneurysms. VA vertebral artery, AICA antero-inferior cerebellar artery, SCA superior-cerebellar artery, BA basilar artery, PCA posterior cerebral artery, P2 P2 segment

of the posterior cerebral artery, VA-BA j. vertebral artery-basilar artery junction. © 2018, Marion Brun, Department of Otorhinolaryngology and Head and Neck Surgery, Centre Hospitalier Vaudois (CHUV)

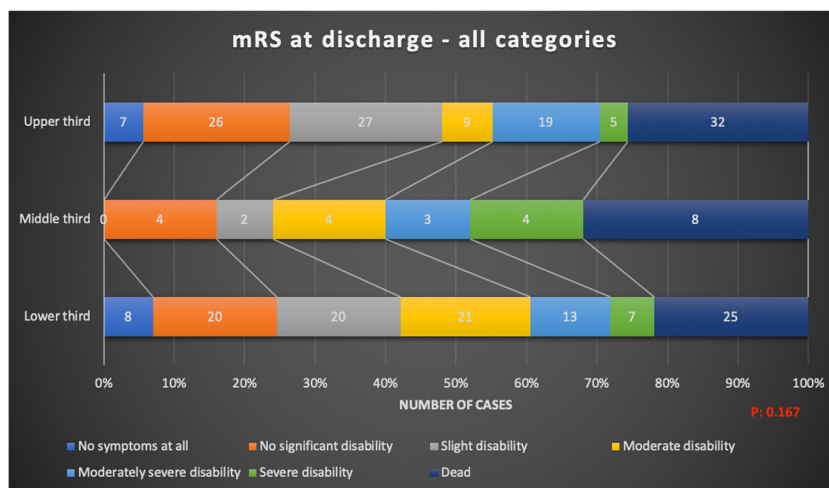
known follow-up date. A log-rank test was applied to compare the survival curves of the three groups. The Kaplan-Meier function was also used to estimate median length of follow-up, with data censored in case of death. We also calculated mean follow-up time for those patients who were still alive at the last follow-up date. We analyzed the data on the statistical package Stata®, version 14 (StataCorp LP, Lakeway Drive, TX, USA).

## Results

### Patients characteristics and aneurysm distribution

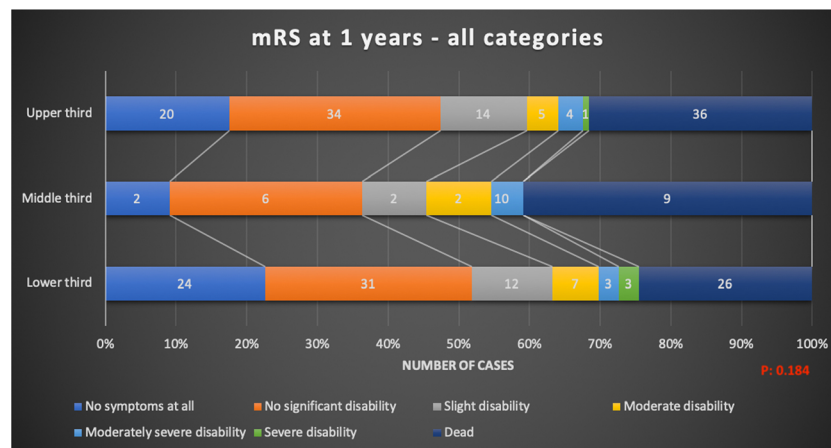
During a period of 6 years, from January 1, 2009, to December 31, 2014, from 1864 eligible aSAH patients, 264

(14.2%) patients presented with a posterior circulation aneurysmal rupture. The mean age was 55.8 year (range 16–88). A female preponderance was observed with 180 women (68.2%). The median follow-up limited to living patients was 0.95 months (range 0.033–79.5) estimated with the Kaplan-Meier method. Overall, ruptured posterior circulation aneurysms were similarly distributed between the upper ( $n = 125, 47.35%$ ) and the lower third ( $n = 114, 43.18%$ ) while the middle third accounted for 9.47% of the overall series ( $n = 25$ ). The detailed distributions are reported in Fig. 1. High (3–5) WFNS score was present in 50% of patients in the upper third location, 60% in the middle third, and 54.4% in the lower third. Cranial nerve deficits at admission were present in 19.6% patients in the upper third, 21.7% in the middle third, and 21.2% in the lower third group. Overall, 16.5% of patients



**Fig. 2** Stacked bar chart of the modified Rankin score (mRS) at discharge. The clinical outcome was assessed with the use of the mRS, an outcome scale assessing handicap in stroke patients (refs here). The seven outcome categories are no symptoms at all, no significant disability despite symptoms (able to carry out all usual duties and activities), slight disability (unable to carry out all

previous activities, but able to look after own affairs without assistance), moderate disability (requiring some help, but able to walk without assistance), moderately severe disability (unable to walk without assistance and unable to attend to own bodily needs without assistance), severe disability (requires constant nursing care and attention, bedridden, incontinent), dead



**Fig. 3** Stacked bar chart of the modified Rankin score (mRS) at 12 months. The clinical outcome was assessed with the use of the mRS, an outcome scale assessing handicap in stroke patients (refs here). The seven outcome categories are no symptoms at all, no significant disability despite symptoms (able to carry out all usual duties and activities), slight disability (unable to carry out all previous activities, but able to look after

own affairs without assistance), moderate disability (requiring some help, but able to walk without assistance), moderately severe disability (unable to walk without assistance and unable to attend to own bodily needs without assistance), severe disability (requires constant nursing care and attention, bedridden, incontinent) dead

presented with epilepsy and 73.3% with ventricular hematoma. Clinical and radiological presentation was similar among the 3 aneurysm groups with no statistical difference in terms of WFNS score at admission, cranial nerve deficit, epilepsy, and ventricular hematoma.

### Treatment modality

Endovascular occlusion was the most common treatment in all 3 groups (72% in the upper third, 68% in the middle third, and 58.8% in the lower third). Surgical treatment was in most cases reserved for aneurysms of the lower third (19.3% vs 6.4% in the upper third and 0% in the middle third respectively). Combined treatment was accomplished in 4% of the upper third patients (5/125), in 12% of the middle third patients (3/25), and 0.9% in the lower third (0.9%). No statistical difference among the distribution of the treatment modality among the three patients subgroups ( $p = 0.004$ , calculated with the Fisher exact test).

Patients with no aneurysm treatment were 17.6% in the upper third (22/125), 20% in the middle third (5/25), and the 21% in the lower third (24/114).

### Complications (Table 1)

Patients presenting with hydrocephalus required external ventricular drainage in 66.6% and ventriculo-peritoneal shunt in 21% of cases. Among the three groups, there was no difference between the rate of temporary and definitive CSF diversion ( $p$  values, 0.65 and 0.5 respectively). No statistically significant difference was found between the three groups for vasospasm requiring endovascular treatment ( $p = 0.26$ ), clinical deterioration attributable do DCI ( $p = 0.1$ ), cerebral

infarction attributable to DCI ( $p = 0.27$ ), or rebleeding prior to aneurysm exclusion ( $p = 0.09$ ).

### Neurological outcome (Figs. 2 and 3)

Overall, favorable outcome (mRS  $\leq 3$ ) was found in 56% (148/264) at discharge and 65.7% (159/264) at 1 year. Clinical outcome in terms of mRS at discharge were as follows:

- Upper third patients: favorable mRS in 55.2% of cases (69/125), unfavorable outcome in 19.2% (24/125), death in 25.6% (32/125)
- Middle third patients: favorable mRS in 40% of cases (10/25), unfavorable mRS in 28% (7/25), death in 32% (8/25)
- Lower third patients: favorable mRS in 60.5% of cases (69/114), unfavorable mRS in 17.5% (20/114), death in 22% (25/114)

Clinical outcome in terms of mRS at 1 year after treatment were as follows:

- Upper third patients: favorable mRS in 64% of cases (73/114), unfavorable outcome in 4.4% (5/114), death in 31.6% (36/114)
- Middle third patients: favorable mRS in 54.5% of cases (12/22), unfavorable mRS in 4.5% (1/22), death in 41% (9/22)
- Lower third patients: favorable mRS in 69.8% of cases (74/106), unfavorable mRS in 5.6% (6/106), death in 24.6% (26/106)



**Table 1** Complications

Complication	Aneurysm location			p value
	Upper third N (%)	Middle third N (%)	Lower third N (%)	
Hydrocephalus with temporary CSF diversion (EVD placement)	78/125 (62.4)	18/25 (72)	76/114 (66.6)	0.65
Hydrocephalus with definitive CSF diversion (VP shunt)	33/125 (26.4)	4/25 (16)	24/114 (21)	0.5
Vasospasm requiring EVT (chemical or mechanical dilatation)	21/125 (16.5)	2/25 (8)	12/114 (10.5)	0.26
Clinical deterioration due to DCI	35/125 (28)	7/25 (28)	19/114 (16.6)	0.1
Cerebral infarction due to DCI	14/125 (11.2)	3/25 (12)	9/114 (7.8)	0.27
Rebleeding before aneurysm treatment	7/125 (5.6)	0	2/114 (1.7)	0.09

P values for the comparisons of the variables among the three aneurysms subgroups calculated with the Fisher exact test

CSF cerebrospinal fluid, DCI delayed cerebral ischemia (see text for details), EVD external ventricular drainage, EVT endovascular treatment, VP shunt ventriculo-peritoneal shunt

### Correlation analysis between clinical, radiological, treatment variables, and mRS at discharge (Table 2)

Age  $\geq 65$  years, high WFNS grade ( $\geq 3$ ), high Fisher grade (3 and 4) ( $p = 0.001$ ) at presentation, and rebleeding before aneurysm occlusion ( $p = 0.001$ ) were correlated to the risk of death or unfavorable neurological outcome at discharge and at 1 year (Table 2). Hydrocephalus was also correlated to an unfavorable neurological outcome at 1 year of follow-up. Mortality during the hospitalization for the upper third patients was 25.6% ( $N = 32$ ), 32% ( $N = 8$ ) for the middle third, and 22.7% ( $N = 25$ ) for the lower third patients (Table 2). The mortality at 1-year follow-up was 31.6% ( $N = 36$ ) for the upper third patients, 40.9% ( $N = 9$ ) for the middle third, and 24.5% ( $N = 26$ ) for the lower third.

### Survival analysis

The Kruskal-Wallis test showed no statistically significant difference in the neurological outcome, in terms of mRS categories at discharge ( $p = 0.20$ ) and after 1 year ( $p = 0.18$ ), between the three groups.

The mortality rate during the overall period of observation was 5%. The mortality rate at follow-up for each aneurysm group was 6.5% for the upper third, 6.9% for the middle third, and 3.6% for the lower third (Fig. 4, panel a). The Kaplan-Meier estimation showed no significant difference in the mortality rate among the different groups ( $p = 0.32$ ) (Fig. 4, panel b).

## Discussion

### Epidemiology

The prevalence of posterior circulation aneurysms in the Swiss SOS cohort (14.2%) is similar to that described in literature (range 10–16%) [1, 14, 21, 22]. We excluded from our analysis

posterior communicating aneurysms because we consider these aneurysms along with anterior circulation aneurysms from an embryologic standpoint, as shown by the similar rate of posterior communicating aneurysms rupture as with the anterior circulation [11]. Coiling was the prevalent treatment modality for aneurysm occlusion in our posterior circulation aSAH patients and this parallels the trend reported in literature [35]. The tendency to endovascular treatment for ruptured posterior circulation aneurysm was well established prior the publication of the ISAT trial, where only 58 patients (2.7%) with posterior circulation aneurysms from their cohort of 2143 were considered for randomization [23]. Surgical occlusion was the treatment modality in 19.3% of patients with ruptured lower third aneurysms (PICA, VA-BA junction and vertebral artery aneurysms), while surgical occlusion was preferred in 6.4% of the upper third ruptured aneurysms and 0% of the middle third. From a general point of view, the more frequent selection of surgical occlusion in lower third patients could be explained by the more favorable surgical exposure of such aneurysms and the possibility to achieve revascularization for complex aneurysm shapes [4, 15, 19]. In the overall series, 5.7% of patients were treated with by pass and half of them presented with a ruptured PICA aneurysm. Further evidence is available from literature supporting our finding of more frequent surgical occlusion in patients with lower third ruptured intracranial aneurysms. For PICA aneurysms, Lanzino and coworkers showed that surgical occlusion should remain the first line choice for ruptured distal PICA aneurysms [26] due to the lower procedure related morbidity of surgery (5.5% vs 7.3%). For VA and VA-BA junction aneurysms, a Japanese multicentric retrospective study demonstrated that surgery is performed acutely in almost half of ruptured VA aneurysms and VA-BA junction with favorable neurological outcomes [45]. The continued need for clipping expertise was also emphasized by the 6-year results of the BRAT trial, reporting a 16% of crossover rate from coiling to clipping in the posterior circulation cohort of ruptured aneurysms [36].

**Table 2** Correlation analysis between clinical, radiological, treatment variables, and mRS at discharge

Variables	mRS at discharge			p value
	Favorable outcome N (%)	Unfavorable outcome N (%)	Dead N (%)	
Age $\geq$ 65 years	22 (36.1)	17 (27.8)	22 (36.1)	0.002*
Female	105 (58.3)	36 (20)	39 (21.7)	0.26*
High WFNS (3 + 4 + 5)	49 (34.5)	40 (28.2)	53 (37.3)	< 0.001*
High Fisher grade (3 + 4)	125 (52.3)	50 (20.9)	64 (26.8)	0.001#
Aneurysm shape (fusiform)	17 (63)	3 (11.1)	7 (25.9)	0.612°
Craniectomy	8 (42.1)	7 (36.8)	4 (21.1)	0.14#
Hydrocephalus	81 (47.1)	44 (25.6)	47 (27.3)	0.03*
Epilepsy	11 (42.3)	8 (30.8)	7 (26.9)	0.23*
Symptomatic vasospasm requiring EVT	20 (57.1)	11 (31.4)	4 (11.4)	0.08#
Rebleeding before aneurysm treatment	1 (11.1)	1 (11.1)	7 (77.8)	0.001#
	mRS at 12 Mo			
Age $\geq$ 65 years	29 (59.9)	4 (7)	24 (42.1)	0.023#
Female	112 (67.9)	9 (5.4)	44 (26.7)	0.42#
High WFNS (3 + 4 + 5)	65 (49.6)	10 (7.6)	56 (42.8)	< 0.001#
High Fisher grade (3 + 4)	137 (62.6)	12 (5.5)	70 (31.9)	0.005#
Aneurysm shape (fusiform)	16 (64)	2 (8)	7 (28)	0.94°
Hydrocephalus	93 (60.4)	9 (5.8)	53 (33.8)	0.004#
Epilepsy	13 (56.5)	2 (8.7)	8 (34.8)	0.32#
Symptomatic vasospasm requiring EVT	23 (71.9)	3 (9.4)	6 (18.7)	0.26#
Rebleeding before aneurysm treatment	2 (22.2)	0	7 (77.8)	0.007#

\*Pearson chi-square, #Fisher exact test, Kruskal-Wallis test, °Mann-Whitney test  
*mRS* modified Rankin score, *EVT* endovascular treatment, *Mo* months

## Neurological outcome

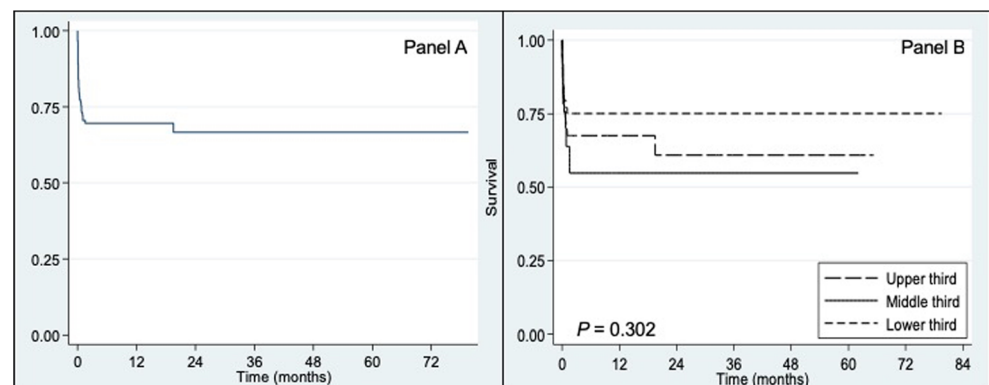
In terms of neurological outcome and mortality rate, our data were similar to those reported previously in literature for ruptured posterior circulation aneurysms [32, 44] [36, 45]. At 1-year follow up, favorable neurological outcome (mRS  $\leq$  3) was reported in two thirds of patients. Nevertheless, if we analyze our results according to the aneurysm location, we found that a favorable clinical outcome (mRS  $\leq$  3) was present in 75% for the upper third and 62.5% in the middle third and 69.9%. The

neurological outcome in our series of ruptured posterior circulation aneurysms remains comparable to that reported in recent literature [8, 10, 12, 16–18, 20, 25, 27, 34, 38–40, 46], with respect to the outcome at 1 year for all three aneurysm locations (Table 3).

## Factors influencing neurological outcome

The correlation analysis found a significant association between severe clinical state at admission after aSAH (High WFNS, 3–5) leading to death or unfavorable clinical outcome at discharge

**Fig. 4** Kaplan-Meier survival estimate of patients with ruptured posterior circulation aneurysms from the Swiss SOS cohort (panel a) and from the same cohort subdivided into 3 groups based on localization (panel b). *p* value was determined by using the log-rank test



**Table 3** Neurological outcome reported in literature for ruptured posterior circulation aneurysms according to the location

Aneurysm artery	Series (yr)	No. of patients	EVT %	Surgery %	% of good outcome at 1 yr
<i>Upper third</i>					
Basilar artery (BA) tip	Tjahjadi [39] (2016)	47	NA	NA	68
	Tjahjadi [40] (2017)	23	100	N/A	69.5
Superior cerebellar artery (SCA)	Patra [25] (2016)	13	46.2	53.8	69.2
Posterior cerebral artery (PCA)	Qin [27] (2017)	20	100	N/A	90
<i>Middle third</i>					
BA trunk	Higa [10] (2011)	6	100	N/A	50
Antero-inferior cerebellar artery (AICA)	Mahmoud [20] (2012)	8	25	75	100
<i>Lower third</i>					
Postero-inferior cerebellar artery (PICA)	Lehto [17] (2014)	68	1.4	98.6	91
	Sejkorova [34] (2017)	65	52.3	47.7	64.6
	Kim [12] (2018)	15	100	N/A	86.6
VA-BA junction	Tjahjadi [3] (2016)	20	N/A	100	58
	Guerrero [8] (2017)	9	100	N/A	78
Vertebral artery (VA)	Zhao [47] (2013)	57	100	N/A	82.4
	Lehto [1] (2015)	131	26.1	64	93
	Lee [16] (2017)	16	100	N/A	50

EVT endovascular treatment, N/A not applicable, NA not available, mRS modified Rankin score, yr. year

and at 1 year. The amount of blood in the subarachnoid cisterns after aSAH was also significantly related to unfavorable outcome at discharge and at 1 year and this is in accordance with the existing literature. [13, 24] Hydrocephalus was also associated with unfavorable neurological outcome at 12 months of follow up, thus confirming the evidence from other studies [7].

Despite a large amount of high WFNS (3–5) and high Fisher grade (3–4) at presentation in our series, the neurological outcome was favorable at follow up in 2/3 of patients. This is a reflection of the high quality of the health care system for management of patients with aSAH in Switzerland, that entails a prompt referral to the neurovascular centers that are equipped with neurosurgeons and interventional radiologists round the clock. Re-bleeding before treatment was more frequently associated with unfavorable outcome and mortality, thus supporting the exiting evidence that re-bleeding is a major cause of morbidity and mortality after aneurysmal SAH and efforts should be attempted to reduce its occurrence [9, 37, 47].

### Study limitations

Despite the rigorous multicentric data collection over 6 years, this study harbors several limitations. The cohort remains too small to perform subgroup analysis. Concerning aneurysms locations, data was lacking from P2 PCA locations also data regarding the specific location (distal vs proximal) were lacking [44]. Data was also lacking about the different types of endovascular treatment used, details regarding crossover

patients, and the grade of aneurysm occlusion (angiography) after both endovascular and surgical treatment. Details regarding the reasons for group of patients in this cohort that received no treatment were not recorded (17.6% in the upper third, 20% in the middle third, and 21% in the lower third) in the registry data. This could bias the outcome analysis due to the potential exclusion of patients with the more complex aneurysms and severe clinical presentations.

### Conclusions

Patients presenting with aneurysmal subarachnoid hemorrhage due to a ruptured posterior circulation aneurysm in the Swiss SOS registry have a favorable outcome in the majority of cases (65.7% mRS 1–3), thus reflecting the high quality of care for aSAH patients in Switzerland. Endovascular occlusion remains the most common treatment modality for ruptured posterior circulation aneurysms in our registry. Surgical treatment was performed in 11.3% of the cohort, principally in patients with aneurysms in the lower third of the posterior circulation. The rate of favorable outcome of this Swiss cohort, that is similar to high volume neurovascular centers worldwide, reflects the importance of care at specialized neurovascular centers for this difficult pathology.

**Acknowledgements** The authors thank all past and present collaborators of the Swiss SOS study group for their support. We also than Madame Marion Brun, Department of Otorhinolaryngology and Head and Neck Surgery, University Hospital of Lausanne (CHUV), for the artist drawing (Fig. 1).

**Funding** The Department of Clinical Neurosurgery of the Lausanne University Hospital provided financial support in the form of funding for the statistical analysis. The sponsor had no role in the design or conduct of this research.

### Compliance with ethical standards

**Conflict of interest** The authors declare that they have no conflict of interest.

**Ethical approval** All procedures performed in studies involving human participants were in accordance with the ethical standards of the local Ethical Committee (Geneva Ethics Committee Board no. 11-233R, NAC 11-085R) and with the 1964 Helsinki declaration and its later amendments or comparable ethical standards.

**Informed consent** For this retrospective type of study, formal consent is not required.

### Appendix. List of contributors to the Swiss SOS study group

- Department of Radiology, Division of Diagnostic and Interventional Neuroradiology, Zurich University Hospital, University of Zurich, Zurich, Switzerland
  - Kulcsár Zsolt, MD
    - Department of Neurosurgery, University Hospital of Zurich & Clinical Neurosciences Center, University of Zurich, Switzerland
  - Emanuela Keller, MD
  - Luca Regli, MD
  - Oliver Bozinov, MD
  - Sina Finkenstädt, MD
    - Department of Neurosurgery, Inselspital Bern, Bern, Switzerland
  - Daniel Schöni, MD
  - Andreas Raabe, MD
  - Jürgen Beck, MD
  - Johannes Goldberg, MD
    - Department of Neurosurgery, University Hospital Basel, Basel, Switzerland
  - Luigi Mariani, MD
  - Raphael Guzman, MD
    - Department of Neurosurgery, Kantonsspital Aarau, Aarau, Switzerland
  - Javier Fandino, MD
  - Daniel Coluccia, MD
    - Department of Radiology, Division of Diagnostic and Interventional Neuroradiology, Ospedale Civico di Lugano, Lugano, Switzerland
  - Cianfoni Alessandro, MD
    - Department of Neurosurgery, Ospedale Regionale di Lugano, Lugano, Switzerland

- Daniele Valsecchi, MD
- Alessio Chiappini, MD
- Alice Venier, MD
- Michael Reinert, MD
  - Department of Radiology, Division of Diagnostic and Interventional Neuroradiology, Kantonsspital St. Gallen, St. Gallen, Switzerland
- Johannes Weber, MD
  - Department of Neurosurgery, Kantonsspital St.Gallen, St.Gallen, Switzerland
- Andrea Ferrari, MD
- Astrid Weyerbrock, MD
- Gerhard Hildebrandt, MD
- Martin Hlavica, MD
  - Department of Radiology, Division of Diagnostic and Interventional Neuroradiology, Hopitaux Universitaires Genève, Geneva, Switzerland
- Vitor Mendes Pereira, MD
  - Department of Neurosurgery, Hopitaux Universitaires de Genève, Geneva, Switzerland
- Marco Corniola, MD
- Karl Schaller, MD

**Publisher's note** Springer Nature remains neutral with regard to jurisdictional claims in published maps and institutional affiliations.

### References

1. Bender MT, Wendt H, Monarch T, Lin LM, Jiang B, Huang J, Coon AL, Tamargo RJ, Colby GP (2017) Shifting treatment paradigms for Ruptured aneurysms from open surgery to endovascular therapy over 25 years. *World Neurosurg* 106:919–924. <https://doi.org/10.1016/j.wneu.2017.07.074>
2. Bijlenga P, Ebeling C, Jaegersberg M, Summers P, Rogers A, Waterworth A, Iavindrasana J, Macho J, Pereira VM, Bukovics P, Vivas E, Sturkenboom MC, Wright J, Friedrich CM, Frangi A, Byrne J, Schaller K, Rufenacht D, neur ISTI (2013) Risk of rupture of small anterior communicating artery aneurysms is similar to posterior circulation aneurysms. *Stroke* 44:3018–3026. <https://doi.org/10.1161/STROKEAHA.113.001667>
3. Burkhardt JK, Neidert MC, Stienen MN, Schoni D, Fung C, Roethlisberger M, Corniola MV, Bervini D, Maduri R, Valsecchi D, Tok S, Schatlo B, Bijlenga P, Schaller K, Bozinov O, Regli L, Swiss SOSsg (2017) Computed tomography angiography spot sign predicts intraprocedural aneurysm rupture in subarachnoid hemorrhage. *Acta Neurochir (Wien)*. <https://doi.org/10.1007/s00701-016-3072-1>
4. D'Ambrosio AL, Kreiter KT, Bush CA, Sciacca RR, Mayer SA, Solomon RA, Connolly ES Jr (2004) Far lateral suboccipital approach for the treatment of proximal posteroinferior cerebellar artery aneurysms: surgical results and long-term outcome. *Neurosurgery* 55:39–50 discussion 50-34
5. de Rooij NK, Linn FH, van der Plas JA, Algra A, Rinkel GJ (2007) Incidence of subarachnoid haemorrhage: a systematic review with emphasis on region, age, gender and time trends. *J Neurol*



- Neurosurg Psychiatry 78:1365–1372. <https://doi.org/10.1136/jnnp.2007.117655>
6. Fisher CM, Kistler JP, Davis JM (1980) Relation of cerebral vasospasm to subarachnoid hemorrhage visualized by computerized tomographic scanning. *Neurosurgery* 6:1–9
  7. Garton T, Keep RF, Wilkinson DA, Strahle JM, Hua Y, Garton HJ, Xi G (2016) Intraventricular hemorrhage: the role of blood components in secondary injury and hydrocephalus. *Transl Stroke Res* 7: 447–451. <https://doi.org/10.1007/s12975-016-0480-8>
  8. Guerrero WR, Ortega-Gutierrez S, Hayakawa M, Derdeyn CP, Rossen JD, Hasan D, Samaniego EA (2018) Endovascular treatment of Ruptured Vertebrobasilar dissecting aneurysms using flow diversion embolization devices: single-institution experience. *World Neurosurg* 109:e164–e169. <https://doi.org/10.1016/j.wneu.2017.09.125>
  9. Han Y, Ye F, Long X, Li A, Xu H, Zou L, Yang Y, You MC (2018) Ultra-early treatment for poor-grade aneurysmal subarachnoid hemorrhage: a systematic review and meta-analysis. *World Neurosurg*. <https://doi.org/10.1016/j.wneu.2018.03.219>
  10. Higa T, Ujiie H, Kato K, Ono Y, Okada Y (2011) Endovascular treatment of basilar trunk saccular aneurysms. *Neuroradiol J* 24: 687–692. <https://doi.org/10.1177/197140091102400504>
  11. Juvela S (2002) Natural history of unruptured intracranial aneurysms: risks for aneurysm formation, growth, and rupture. *Acta Neurochir Suppl* 82:27–30
  12. Kim J, Chang C, Jung YJ (2018) Coil embolization results of the Ruptured proximal posterior inferior cerebellar artery Aneurysm: a single-center 10 Years' experience. *World Neurosurg* 117:e645–e652. <https://doi.org/10.1016/j.wneu.2018.06.105>
  13. Klimo P Jr, Schmidt RH (2006) Computed tomography grading schemes used to predict cerebral vasospasm after aneurysmal subarachnoid hemorrhage: a historical review. *Neurosurg Focus* 21:E5
  14. Korja M, Kivisaari R, Rezaei Jahromi B, Lehto H (2017) Size and location of ruptured intracranial aneurysms: consecutive series of 1993 hospital-admitted patients. *J Neurosurg* 127:748–753. <https://doi.org/10.3171/2016.9.JNS161085>
  15. Krayenbuhl N, Guerrero C, Krisht AF (2005) Technical strategies to approach aneurysms of the vertebral and posterior inferior cerebellar arteries. *Neurosurg Focus* 19:E4
  16. Lee M, Park IS, Lee KH, Park H, Lee CH, Han JW (2017) Endovascular treatments for Ruptured intracranial vertebral artery dissecting aneurysms: experience in 16 patients. *J Cerebrovasc Endovasc Neurosurg* 19:268–275. <https://doi.org/10.7461/jcen.2017.19.4.268>
  17. Lehto H, Harati A, Niemela M, Dashti R, Laakso A, Elsharkawy A, Satopaa J, Billon-Grand R, Canato B, Kivisaari R, Hernesniemi J (2014) Distal posterior inferior cerebellar artery aneurysms: clinical features and outcome of 80 patients. *World Neurosurg* 82:702–713. <https://doi.org/10.1016/j.wneu.2014.06.012>
  18. Lehto H, Niemela M, Kivisaari R, Laakso A, Jahromi BR, Hijazy F, Andrade-Barazarte H, Dashti R, Hernesniemi J (2015) Intracranial vertebral artery aneurysms: clinical features and outcome of 190 patients. *World Neurosurg* 84:380–389. <https://doi.org/10.1016/j.wneu.2015.03.034>
  19. Liew D, Ng PY, Ng I (2004) Surgical management of ruptured and unruptured symptomatic posterior inferior cerebellar artery aneurysms. *Br J Neurosurg* 18:608–612
  20. Mahmoud M, El Serwi A, Alaa Habib M, Abou Gamrah S (2012) Endovascular treatment of AICA flow dependent aneurysms. A report of three cases and review of the literature. *Interv Neuroradiol* 18:449–457. <https://doi.org/10.1177/159101991201800411>
  21. McDougall CG, Spetzler RF, Zabramski JM, Partovi S, Hills NK, Nakaji P, Albuquerque FC (2012) The Barrow Ruptured Aneurysm trial. *J Neurosurg* 116:135–144. <https://doi.org/10.3171/2011.8.JNS101767>
  22. Miller TS, Altschul D, Baxi N, Farinhas J, Pasquale D, Burns J, Gordon D, Bello J, Brook A, Flamm E (2017) Comparison of the prevalence of Ruptured and Unruptured cerebral aneurysms in a poor urban minority population. *J Stroke Cerebrovasc Dis* 26: 2287–2293. <https://doi.org/10.1016/j.jstrokecerebrovasdis.2017.05.012>
  23. Molyneux A, Kerr R, Stratton I, Sandercock P, Clarke M, Shrimpton J, Holman R, International Subarachnoid Aneurysm Trial Collaborative G (2002) International subarachnoid Aneurysm trial (ISAT) of neurosurgical clipping versus endovascular coiling in 2143 patients with ruptured intracranial aneurysms: a randomised trial. *Lancet* 360:1267–1274
  24. Neider MC, Maldaner N, Stienen MN, Roethlisberger M, Zumofen DW, D'Alonzo D, Marbacher S, Maduri R, Hostettler IC, Schatlo B, Schneider MM, Seule MA, Schoni D, Goldberg J, Fung C, Arrighi M, Valsecchi D, Bijlenga P, Schaller K, Bozinov O, Regli L, Burkhardt JK, Swiss SOSsg (2018) The Barrow neurological institute grading scale as a predictor for delayed cerebral ischemia and outcome after aneurysmal subarachnoid hemorrhage: data from a Nationwide patient registry (Swiss SOS). *Neurosurgery*. <https://doi.org/10.1093/neuros/nyx609>
  25. Patra DP, Bir SC, Maiti TK, Kalakoti P, Cuellar-Saenz HH, Guthikonda B, Sun H, Nanda A (2016) Superior cerebellar artery aneurysms, the "sui generis" in posterior circulation: the role of microsurgery in the endovascular era. *World Neurosurg* 94:229–238. <https://doi.org/10.1016/j.wneu.2016.07.007>
  26. Petr O, Sejkorova A, Bradac O, Brinjikji W, Lanzino G (2016) Safety and efficacy of treatment strategies for posterior inferior cerebellar artery aneurysms: a systematic review and meta-analysis. *Acta Neurochir* 158:2415–2428. <https://doi.org/10.1007/s00701-016-2965-3>
  27. Qin X, Xu F, Maimaiti Y, Zheng Y, Xu B, Leng B, Chen G (2017) Endovascular treatment of posterior cerebral artery aneurysms: a single center's experience of 55 cases. *J Neurosurg* 126:1094–1105. <https://doi.org/10.3171/2016.1.JNS152447>
  28. Report of World Federation of Neurological Surgeons Committee on a Universal Subarachnoid Hemorrhage Grading Scale (1988) *J Neurosurg* 68:985–986
  29. Rhoton AL Jr (2002) The supratentorial arteries. *Neurosurgery* 51: S53–S120
  30. Rinkel GJ, Djibuti M, Algra A, van Gijn J (1998) Prevalence and risk of rupture of intracranial aneurysms: a systematic review. *Stroke* 29:251–256
  31. Roethlisberger M, Achermann R, Bawarjan S, Stienen MN, Fung C, D'Alonzo D, Maldaner N, Ferrari A, Corniola MV, Schoni D, Goldberg J, Valsecchi D, Robert T, Maduri R, Seule MA, Burkhardt JK, Marbacher S, Bijlenga P, Blackham KA, Bucher HC, Mariani L, Guzman R, Zumofen DW, SOSsg S (2018) Impact of Aneurysm multiplicity on treatment and outcome after aneurysmal subarachnoid hemorrhage. *Neurosurgery*. <https://doi.org/10.1093/neuros/nyy331>
  32. Sanai N, Tarapore P, Lee AC, Lawton MT (2008) The current role of microsurgery for posterior circulation aneurysms: a selective approach in the endovascular era. *Neurosurgery* 62:1236–1249; discussion 1249–1253. <https://doi.org/10.1227/01.neu.0000333295.59738.de>
  33. Schatlo B, Fung C, Fathi AR, Sailer M, Winkler K, Daniel RT, Bijlenga P, Ahlborn P, Seule M, Zumofen D, Reinert M, Woernle C, Stienen M, Levivier M, Hildebrandt G, Mariani L, Bernays R,

- Fandino J, Raabe A, Keller E, Schaller K (2012) Introducing a nationwide registry: the Swiss study on aneurysmal subarachnoid haemorrhage (Swiss SOS). *Acta Neurochir* 154:2173–2178; discussion 2178. <https://doi.org/10.1007/s00701-012-1500-4>
34. Sejkorova A, Petr O, Mulino M, Cihlar J, Hejcl A, Thome C, Sames M, Lanzino G (2017) Management of posterior inferior cerebellar artery aneurysms: what factors play the most important role in outcome? *Acta Neurochir* 159:549–558. <https://doi.org/10.1007/s00701-016-3058-z>
  35. Spetzler RF, McDougall CG, Albuquerque FC, Zabramski JM, Hills NK, Partovi S, Nakaji P, Wallace RC (2013) The Barrow Ruptured Aneurysm trial: 3-year results. *J Neurosurg* 119:146–157. <https://doi.org/10.3171/2013.3.JNS12683>
  36. Spetzler RF, McDougall CG, Zabramski JM, Albuquerque FC, Hills NK, Russin JJ, Partovi S, Nakaji P, Wallace RC (2015) The Barrow Ruptured Aneurysm trial: 6-year results. *J Neurosurg* 123: 609–617. <https://doi.org/10.3171/2014.9.JNS141749>
  37. Stienen MN, Germans M, Burkhardt JK, Neidert MC, Fung C, Bervini D, Zumofen D, Rothlisberger M, Marbacher S, Maduri R, Robert T, Seule MA, Bijlenga P, Schaller K, Fandino J, Smoll NR, Maldaner N, Finkenstadt S, Esposito G, Schatlo B, Keller E, Bozinov O, Regli L, Swiss SOSSG (2018) Predictors of in-hospital death after aneurysmal subarachnoid hemorrhage: analysis of a Nationwide database (Swiss SOS [Swiss Study on aneurysmal subarachnoid hemorrhage]). *Stroke* 49:333–340. <https://doi.org/10.1161/STROKEAHA.117.019328>
  38. Tjahjadi M, Kivelev J, Serrone JC, Maekawa H, Kerro O, Jahromi BR, Lehto H, Niemela M, Hernesniemi JA (2016) Factors determining surgical approaches to basilar bifurcation aneurysms and its surgical outcomes. *Neurosurgery* 78:181–191. <https://doi.org/10.1227/NEU.0000000000001021>
  39. Tjahjadi M, Niemela M, Kivelev J, Serrone J, Maekawa H, Jahromi BR, Kerro O, Hafez A, Lehto H, Kivisaari R, Hernesniemi J (2016) Presigmoid approach to Vertebrobasilar artery aneurysms: a series of 31 patients and review of the literature. *World Neurosurg* 92: 313–322. <https://doi.org/10.1016/j.wneu.2016.05.001>
  40. Tjahjadi M, Kim T, Ojar D, Byoun HS, Lee SU, Ban SP, Hwang G, Kwon OK (2017) Long-term review of selected basilar-tip aneurysm endovascular techniques in a single institution. *Interdisciplinary Neurosurg* 8:50–56. <https://doi.org/10.1016/j.inat.2017.01.005>
  41. van Swieten JC, Koudstaal PJ, Visser MC, Schouten HJ, van Gijn J (1988) Interobserver agreement for the assessment of handicap in stroke patients. *Stroke* 19:604–607
  42. Vergouwen MD, Vermeulen M, van Gijn J, Rinkel GJ, Wijdicks EF, Muizelaar JP, Mendelow AD, Juvela S, Yonas H, Terbrugge KG, Macdonald RL, Diring MN, Broderick JP, Dreier JP, Roos YB (2010) Definition of delayed cerebral ischemia after aneurysmal subarachnoid hemorrhage as an outcome event in clinical trials and observational studies: proposal of a multidisciplinary research group. *Stroke* 41:2391–2395. <https://doi.org/10.1161/STROKEAHA.110.589275>
  43. Vergouwen MD, Jong-Tjien-Fa AV, Algra A, Rinkel GJ (2016) Time trends in causes of death after aneurysmal subarachnoid hemorrhage: a hospital-based study. *Neurology* 86:59–63. <https://doi.org/10.1212/WNL.0000000000002239>
  44. Williamson RW, Wilson DA, Abla AA, McDougall CG, Nakaji P, Albuquerque FC, Spetzler RF (2015) Clinical characteristics and long-term outcomes in patients with ruptured posterior inferior cerebellar artery aneurysms: a comparative analysis. *J Neurosurg* 123: 441–445. <https://doi.org/10.3171/2014.10.JNS141079>
  45. Yasui N, Hadeishi H, Nishimura H, Uemura K, Tohoku Ruptured Vertebro-basilar Aneurysm Study G (2003) Cooperative study of ruptured vertebrobasilar artery aneurysms in the Tohoku district in Japan. *Neurol Med Chir (Tokyo)* 43:219–226 discussion 227
  46. Zhao KJ, Fang YB, Huang QH, Xu Y, Hong B, Li Q, Liu JM, Zhao WY, Deng BQ (2013) Reconstructive treatment of Ruptured intracranial spontaneous vertebral artery dissection aneurysms: Long-term results and predictors of unfavorable outcomes. *PLoS One* 8: e67169. <https://doi.org/10.1371/journal.pone.0067169>
  47. Zhao B, Fan Y, Xiong Y, Yin R, Zheng K, Li Z, Tan X, Yang H, Zhong M, Group AS (2016) Aneurysm rebleeding after poor-grade aneurysmal subarachnoid hemorrhage: predictors and impact on clinical outcomes. *J Neurol Sci* 371:62–66. <https://doi.org/10.1016/j.jns.2016.10.020>
  48. Zumofen DW, Roethlisberger M, Achermann R, Bawarjan S, Stienen MN, Fung C, D'Alonzo D, Maldaner N, Ferrari A, Corniola MV, Schoeni D, Goldberg J, Valsecchi D, Robert T, Maduri R, Seule M, Burkhardt JK, Marbacher S, Bijlenga P, Blackham KA, Bucher HC, Mariani L, Guzman R, Swiss SOSSG (2018) Factors associated with clinical and radiological status on admission in patients with aneurysmal subarachnoid hemorrhage. *Neurosurg Rev* 41:1059–1069. <https://doi.org/10.1007/s10143-018-0952-2>

### Previous presentations

The results of this study were presented in part at the European Association of Neurosurgical Societies (EANS) in Athens on September 4, 2016.

### Affiliations

Rodolfo Maduri<sup>1</sup>  · Daniele Starnoni<sup>1</sup> · Alda Rocca<sup>1</sup> · David Bervini<sup>2</sup> · Daniel Walter Zumofen<sup>3,4</sup> · Martin Nikolaus Stienen<sup>5</sup> · Bawarjan Schatlo<sup>6</sup> · Christian Fung<sup>7</sup> · Thomas Robert<sup>8</sup> · Martin A. Seule<sup>9</sup> · Jan-Karl Burkhardt<sup>5,10</sup> · Nicolai Maldaner<sup>5</sup> · Michel Rothlisberger<sup>3</sup> · Kristine A. Blackham<sup>4</sup> · Serge Marbacher<sup>11</sup> · Donato D'Alonzo<sup>11</sup> · Luca Remonda<sup>12</sup> · Paolo Machi<sup>13</sup> · Jan Gralla<sup>14</sup> · Philippe Bijlenga<sup>15</sup> · Guillaume Saliou<sup>16</sup> · Pierluigi Ballabeni<sup>17,18</sup> · Marc Levivier<sup>1,18</sup> · Mahmoud Messerer<sup>1,18</sup> · Roy Thomas Daniel<sup>1,18</sup>

<sup>1</sup> Department of Clinical Neurosciences, Service of Neurosurgery, Lausanne University Hospital (CHUV), 46 rue du Bugnon, 1011 Lausanne, Switzerland

<sup>2</sup> Department of Neurosurgery, Inselspital, University of Bern, Bern, Switzerland

<sup>3</sup> Department of Neurosurgery, Basel University Hospital, Basel, Switzerland

<sup>4</sup> Diagnostic and Interventional Neuroradiology Section, Department of Radiology, Basel University Hospital, Basel, Switzerland

- <sup>5</sup> Department of Neurosurgery, University Hospital of Zurich & Clinical Neurosciences Center, University of Zurich, Zurich, Switzerland
- <sup>6</sup> Department of Neurosurgery, University Hospital Göttingen, Göttingen, Germany
- <sup>7</sup> Department of Neurosurgery, Medical Center, University of Freiburg, Freiburg, Germany
- <sup>8</sup> Department of Neurosurgery, Ospedale Civico di Lugano, Lugano, Switzerland
- <sup>9</sup> Department of Neurosurgery, Kantonsspital St. Gallen, St. Gallen, Switzerland
- <sup>10</sup> Department of Neurosurgery, Baylor Medical Center & College of Medicine, Houston, TX, USA
- <sup>11</sup> Department of Neurosurgery, Kantonsspital Aarau, Aarau, Switzerland
- <sup>12</sup> Department of Radiology, Division of Diagnostic and Interventional Neuroradiology, Kantonsspital Aarau, Aarau, Switzerland
- <sup>13</sup> Department of Radiology, Division of Diagnostic and Interventional Neuroradiology, Geneva University Hospital (HUG), Geneva, Switzerland
- <sup>14</sup> Department of Radiology, Division of Diagnostic and Interventional Neuroradiology, Inselspital, University of Bern, Bern, Switzerland
- <sup>15</sup> Department of Neurosurgery, Hopitaux Universitaires Genève, Geneva, Switzerland
- <sup>16</sup> Department of Radiology, Division of Diagnostic and Interventional Neuroradiology, Lausanne University Hospital (CHUV), Lausanne, Switzerland
- <sup>17</sup> Lausanne Institute for Clinical Epidemiology and Biostatistics, University Hospital Lausanne (CHUV), Lausanne, Switzerland
- <sup>18</sup> University of Lausanne (UniL), Lausanne, Switzerland