

SPECIAL ARTICLE



Common Data Elements for Radiological Imaging of Patients with Subarachnoid Hemorrhage: Proposal of a Multidisciplinary Research Group

Katharina A. M. Hackenberg^{1*} , Nima Etminan^{1†}, Max Wintermark², Philip M. Meyers³, Giuseppe Lanzino⁴, Daniel Rüfenacht⁵, Timo Krings⁶, John Huston 3rd⁷, Gabriel Rinkel⁸ and Colin Derdeyn^{9†} on behalf of the Unruptured Intracranial Aneurysms and SAH CDE Project Investigators

© 2019 Neurocritical Care Society

Abstract

Introduction: Lack of homogeneous definitions for imaging data and consensus on their relevance in the setting of subarachnoid hemorrhage and unruptured intracranial aneurysms lead to a difficulty of data pooling and lack of robust data. The aim of the National Institute of Health/National Institute of Neurological Disorders and Stroke, Unruptured Intracranial Aneurysm (UIA) and Subarachnoid Hemorrhage (SAH) Common Data Elements (CDE) Project was to standardize data elements to ultimately facilitate data pooling and establish a more robust data quality in future neurovascular research on UIA and SAH.

Methods: For the subcommittee 'Radiological imaging of SAH', international cerebrovascular specialists with imaging expertise in the setting of SAH were selected by the steering committee. CDEs were developed after reviewing the literature on neuroradiology and already existing CDEs for other neurological diseases. For prioritization, the CDEs were classified into 'Core,' 'Supplemental—Highly Recommended,' 'Supplemental' and 'Exploratory.'

Results: The subcommittee compiled 136 CDEs, 100 out of which were derived from previously established CDEs on ischemic stroke and 36 were newly created. The CDEs were assigned to four main categories (several CDEs were assigned to more than one category): 'Parenchymal imaging' with 42 CDEs, 'Angiography' with 49 CDEs, 'Perfusion imaging' with 20 CDEs, and 'Transcranial doppler' with 55 CDEs. The CDEs were classified into core, supplemental highly recommended, supplemental and exploratory elements. The core CDEs were *imaging modality, imaging modality type, imaging modality vessel, angiography type, vessel angiography arterial anatomic site and imaging vessel angiography arterial result*.

Conclusions: The CDEs were established based on the current literature and consensus across cerebrovascular specialists. The use of these CDEs will facilitate standardization and aggregation of imaging data in the setting of SAH. However, the CDEs may require reevaluation and periodic adjustment based on current research and improved imaging quality and novel modalities.

*Correspondence: katharina.hackenberg@umm.de

†Nima Etminan and Colin Derdeyn shared authorship.

¹ Department of Neurosurgery, Medical Faculty Mannheim, University Hospital Mannheim, University of Heidelberg, Theodor-Kutzer-Ufer 1-3, 68167 Mannheim, Germany

Full list of author information is available at the end of the article

Keywords: Common data elements, Imaging, Subarachnoid hemorrhage, Unruptured intracranial aneurysms, Digital subtraction angiography, Data standardization

Introduction

The National Institute of Neurological Disorders and Stroke (NINDS) began an effort to standardize and harmonize data collection in 2006. The goal of this project was to standardize naming, data definitions, data structure, and response options for variables used in NINDS-funded research [1]. A NINDS effort to develop common data elements (CDEs) for stroke research was launched in 2011 [2]. Eight working groups (WGs) were created, including one focused on imaging. Stroke-related CDEs have been curated and updated by a standing group on an annual basis.

The NINDS Stroke CDEs initially focused on ischemic stroke trials. Many of the variables important for research on unruptured intracranial aneurysms (UIA) and subarachnoid hemorrhage (SAH) were not included. The purpose of this project was to develop a menu of data names, definitions, and response options for investigators designing trials for SAH prevention, treatment, or recovery. Use of these CDEs will facilitate communication and progress in our field.

The focus of this WG was to develop CDEs for imaging. These include vascular imaging of intracranial aneurysms and large artery vasospasm, parenchymal imaging to define SAH and infarction, and perfusion imaging to define perfusion abnormalities, among others.

Many variables, such as imaging modality for example, have been defined previously by the NINDS Stroke project, and these imaging modalities were carried forward to ensure ease of use and communication.

Methods

The UIA and SAH CDE project is described by Suarez et al. [3] The Steering Committee for the UIA and SAH CDE project identified individuals with expertise in cerebrovascular disease and imaging and assigned two co-chairs (NE and CD). Individuals were tasked with identifying from the existing NINDS Stroke CDEs or developing new CDEs for the following nine separate imaging domains (Fig. 1).

The topics and the responsible WG members were:

- Computerized tomography (CT)/CT-Angiography/CT-Perfusion (MW)
- Transcranial doppler sonography (KH)
- Digital subtraction angiography (PM)
- Magnetic resonance (MR) imaging/MR-Angiography (MW)
- Aneurysm morphology (NE, DR)
- Computational fluid dynamics (CFD) (NE)
- SAH grading scales (CD)
- Aneurysm types (TK)

These subcommittees then proposed CDEs, the corresponding definitions as well classification according to relevance for future studies into four groups for the underlying topic to the remaining subcommittee members: (1) Core CDEs—elements which can be consistently collected across studies and which should be employed in studies concerning the corresponding disease or therapeutic area, (2) Supplemental—Highly Recommended CDEs—elements that are essentially based on certain conditions or study types in clinical research studies and that are strongly recommended for the specific disease or therapeutic area,

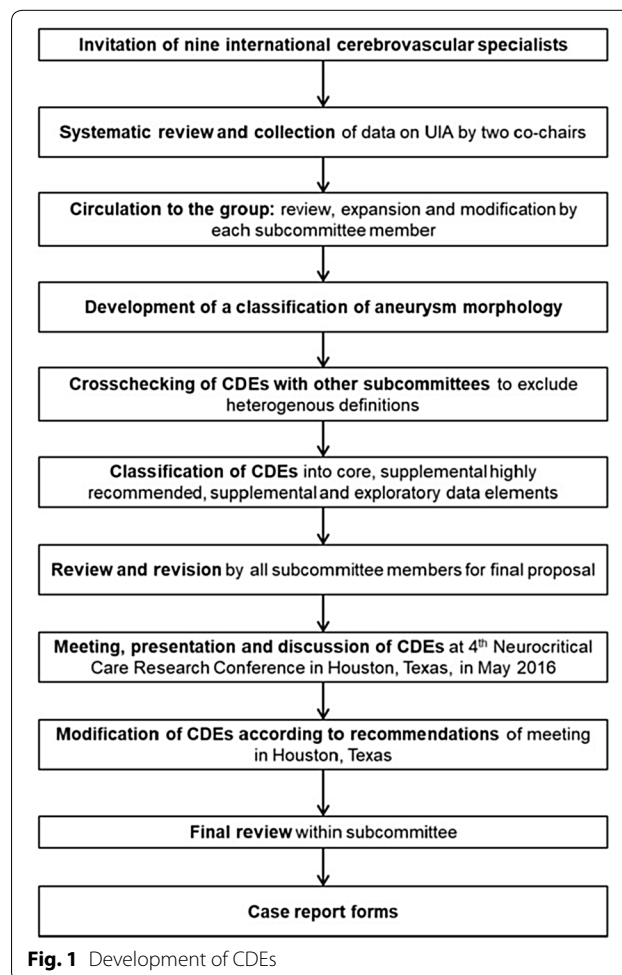


Fig. 1 Development of CDEs

(3) Supplemental CDEs—elements that are commonly collected in clinical research studies, but whose relevance depends on the study design or type of research and (4) Exploratory CDEs—elements which are reasonable to use, but whose validity is limited due to insufficient availability of data, so they require further validation.

Previously established CDEs from other entities were reviewed, adapted for the UIA and SAH CDE project and proposed to all subcommittee members for review via email. The CDE definitions and categorization were reviewed by the two co-chairs, and after a final round of review and agreement by each subcommittee member, case report forms were developed.

Imaging Common Data Elements Overview

A total of 136 CDEs on imaging for SAH were developed. These include 97 previously established CDEs from other neurological diseases; three previously established CDEs which were modified for the UIA and SAH CDE project; and 36 new CDEs. Forty-two CDEs were classified to ‘Parenchymal imaging,’ 49 to ‘Angiography,’ 20 to ‘Perfusion imaging,’ and 55 to ‘Transcranial doppler.’ Each of the CDEs were assigned a specific identification number, a CDE name, variable name, definition, classification, permissible value, a code name, a code description and, if necessary, a unit of measure as well as a question text. If a CDE was assigned to more than one category, it retained its unique identification number. In addition, if the CDE was pulled from the NINDS Stroke CDEs, it retained that identification number. According to the priority in the main category, the CDEs were classified.

Parenchymal Imaging

Forty of the 42 CDEs in the main category ‘Parenchymal imaging’ were adopted directly from pre-existing CDEs, one was edited, and one was newly created. Out of the 42 CDEs, *Imaging modality* and *Imaging modality type* were classified as Core (Table 1).

The 21 Supplemental—Highly Recommended CDEs were:

- Imaging study ID number
- Imaging study date and time
- Imaging acquisition reason
- Imaging acquisition reason other text
- Imaging slice thickness value
- Imaging computed tomography angiography source used indicator
- Intraventricular hemorrhage status
- Graeb intraventricular hemorrhage scale—right lateral ventricle score [4]
- Graeb intraventricular hemorrhage scale—left lateral ventricle score

- Graeb intraventricular hemorrhage scale—third ventricle score
- Graeb intraventricular hemorrhage scale—fourth ventricle score
- Graeb intraventricular hemorrhage scale—total score
- Intraventricular hemorrhage volume measurement
- Subarachnoid hemorrhage indicator
- Fisher scale grade [5]
- Modified Fisher scale grade [6]
- Subdural hematoma present indicator
- Subdural hematoma type
- Hydrocephalus present indicator
- Arteriovenous malformation present indicator
- Arteriovenous malformation anatomic site

The remaining Supplemental and/or Exploratory CDEs are listed in Table 1.

Angiography

The category ‘Angiography’ comprises 49 CDEs, of which 20 were entirely reutilized, two were previously established modified, and 27 were novel. This category was further divided into the subtopics (A) ‘Vascular imaging,’ (B) ‘Endovascular treatment’ and (C) ‘CFD: Volumetric factors,’ ‘CFD: Surface factors’ and ‘CFD: Hemodynamic factors.’ In this category, three CDEs were defined as Core (*Imaging modality vessel imaging angiography type*, *imaging vessel angiography arterial anatomic site*, and *imaging vessel angiography arterial result*).

The 15 Supplemental—Highly Recommended CDEs were:

- Imaging study ID number
- Imaging study date and time
- Acquisition reason
- Acquisition reason other text
- Magnetic resonance angiography type
- CT angiography type
- Imaging vessel angiography level of confidence status
- Imaging vessel angiography aneurysm anatomic site
- Imaging aneurysm anatomic site
- Imaging aneurysm dome measurement
- Imaging aneurysm neck measurement
- Imaging unruptured intracranial aneurysm morphology type
- Imaging aneurysm aspect ratio value
- Aneurysm occlusion percentage value
- Aneurysm occlusion Raymond–Roy classification category [7]

The remaining 18 Supplemental and 13 Exploratory elements are listed in Table 2.

Table 1 CDEs—parenchymal imaging

CDE ID	CDE name	Definition	Permissible value	Classification
C13750	Imaging study ID number	Unique identification number assigned to the study or assessment session		Supplemental—highly recommended
C02494	Imaging study date and time	Date (and time, if applicable and known), the radiologic study was obtained		Supplemental—highly recommended
C18888	Imaging acquisition reason other text	The free-text field related to 'Imaging acquisition reason' specifying other text. Describes why the imaging study was performed		Supplemental—highly recommended
C13751	Imaging acquisition reason	Describes why the imaging study was performed	Diagnostic; post-treatment; monitoring	Supplemental—highly recommended
C18701	Imaging modality other text	The free-text field related to 'Imaging modality type' specifying other text. Type of radiologic study performed on the participant/subject		Core
C02437 modified	Imaging modality type	Type of radiologic study performed on the participant/subject	Non-contrast CT; contrast CT; post-contrast CT; CT-angiography; CT perfusion; CBCT; PET; SPECT; MRI; non-contrast MRI; contrast MRI; MRI-angiography; MRI perfusion; X-Ray angiography; OCT; microscopy; MEG; EEG; MEG; DEXA; ultrasound	Core
C18718	Imaging scanner strength other text	The free-text field related to 'Imaging scanner strength value' specifying other text. Value, in Tesla (T), of the scanner's magnetic field strength used for the scan being reported		Supplemental
C02495	Imaging scanner strength value	Value, in Tesla (T), of the scanner's magnetic field strength used for the scan being reported	1.5; 3.0; 4.0; 7.0	Supplemental
C18708	Imaging pulse sequence other text	The free-text field related to 'Imaging pulse sequence type' specifying other text. Type of imaging pulse sequence used		Supplemental
C02499	Imaging pulse sequence type	Type of imaging pulse sequence used	T1; T2; FLAIR; DWI; GRE; SWI; DTI; MRSI; PWI; gradient-echo; pulsed-ASL; continuous-ASL; pseudocontinuous-ASL; post-contrast FLAIR; post-contrast T1-weighted; COW MRA; TOF Neck MRA; CE MRA; FLASH; MPRAGE; SPGR; SPACE/VISTA; TSE/FSE; dual echo PD/T2 W SE; PD SE; T2 W SE; T1 W SE; T1 W 3D gradient-echo; T1-weighted spin echo with contrast; T1-weighted spin echo without contrast; PD/T2W FSE; DIR; PSIR; fMRI; PRESS; spectroscopic imaging 2D; spectroscopic imaging 3D; Spin echo; STEAM; single voxel spectroscopy (SVS); pulsed-ASL; continuous-ASL; pseudocontinuous-ASL; multivoxel spectroscopy; unlocalized spectroscopy; ISIS; DWI/ADC; reduced field of view (rFOV); echo planar imaging (EPI)	Supplemental

Table 1 (continued)

CDE ID	CDE name	Definition	Permissible value	Classification
C08244	Imaging slice thickness value	Value of the thickness of the slice measured in millimeters		Supplemental—highly recommended
C13752	Imaging computed tomography angiography (CTA) source used indicator	Indicates whether computed tomography angiography (CTA) source imaging was used	Yes; no; unknown	Supplemental—highly recommended
NEW	Imaging CT slice value	Value for the number of slices of the CT	64; 128; 256; 320; other, specify	Supplemental
C13754	Imaging CT settings window value	Value for the window of the CT window and level settings		Supplemental
C13755	Imaging CT settings level value	Value for the level of the CT window and level settings		Supplemental
C18720	Imaging visual analysis location performed other text	The free-text field related to 'Imaging visual analysis location performed type' specifying other text. Location where visual analysis of the imaging data is performed		Supplemental
C08254	Imaging visual analysis location performed type	Location where visual analysis of the imaging data is performed	Central; central read; local-site; local read; local report	Supplemental
C08255	Imaging visual analysis blinded indicator	Indicator of whether the visual analysis was performed blinded to clinical data	Yes; no; unknown	Supplemental
C10931	Imaging quality of images technically satisfactory indicator	Indicator of whether the quality of the images were technically satisfactory	Yes; no; unknown; not applicable	Supplemental
C02446	Intraventricular hemorrhage status	Indicator of acute-appearing blood within the ventricles.	Present; absent; indeterminate	Supplemental—highly recommended
C13831	Graeb intraventricular hemorrhage (IVH) scale—right lateral ventricle score	Indicates Graeb IVH scale—right lateral ventricle score	1 (trace amount of blood or mild bleeding); 2 (< half of the ventricle filled with blood); 3 (> half of the ventricle filled with blood); 4 (ventricle expanded and filled with blood)	Supplemental—highly recommended
C13832	Graeb intraventricular hemorrhage (IVH) scale—left lateral ventricle score	Indicates Graeb IVH scale—left lateral ventricle score	1 (trace amount of blood or mild bleeding); 2 (< half of the ventricle filled with blood); 3 (> half of the ventricle filled with blood); 4 (ventricle expanded and filled with blood)	Supplemental—highly recommended
C13833	Graeb intraventricular hemorrhage (IVH) scale—third ventricle score	Indicates Graeb IVH Scale—third ventricle score	1 (blood present without dilatation); 2 (ventricle expanded and filled with blood)	Supplemental—highly recommended
C13834	Graeb intraventricular hemorrhage (IVH) scale—fourth ventricle score	Indicates Graeb IVH scale—fourth ventricle score	1 (blood present without dilatation); 2 (ventricle expanded and filled with blood)	Supplemental—highly recommended
C13835	Graeb intraventricular hemorrhage (IVH) scale—total score	Indicates Graeb IVH scale—total score		Supplemental—highly recommended
C02445	Intraventricular hemorrhage volume measurement	Measured volume in cubic centimeters of intraventricular hemorrhage		Supplemental—highly recommended
C02469	Subarachnoid hemorrhage indicator	Indicator of macroscopic blood located between the brain surface and the arachnoid membrane. On CT and MR, the blood in this location will follow the contour of the sulci and cisterns. Acute SAH is hyperdense on CT and hyperintense on FLAIR MR imaging	Present; absent; indeterminate	Supplemental—highly recommended

Table 1 (continued)

CDE ID	CDE name	Definition	Permissible value	Classification
C13836	Fisher grade	Indicates Fisher grade	1 (no hemorrhage evident); 2 (SAH less than 1 mm thick); 3 (SAH more than 1 mm thick); 4 (SAH of any thickness with IVH or parenchymal extension)	Supplemental—highly recommended
C13837	Modified Fisher scale grade	Indicates modified Fisher scale grade	0 (No SAH or IVH) 1 (SAH less than 1 mm thick, no IVH); 2 (SAH less than 1 mm thick, with IVH); 3 (SAH more than 1 mm thick, no IVH); 4 (SAH more than 1 mm thick, with IVH)	Supplemental—highly recommended
C13838	Hijdra scale anatomic site	The site for the Hijdra scale assessment (the Hijdra et al. (1990) described a method to grade the amount of blood in the SA space and ventricles on CT)	Frontal; lateral sylvian right; lateral sylvian left; basilar sylvian right; basilar sylvian left; suprasellar right; suprasellar left; ambient right; ambient left; quadrigeminal; fourth ventricle; lateral ventricle right; lateral ventricle left	Supplemental
C13839	Hijdra scale value	Indicates Hijdra scale—value	0 (no amount of blood); 1 (small amount of blood (cisterns), sedimentation of blood in the posterior part (ventricles)); 2 (moderately filled with blood (cisterns), partly filled with blood (ventricles)); 3 (completely filled with blood)	Supplemental
C14050	Hijdra scale total score	Indicates Hijdra scale—total score		Supplemental
C13840	Subdural hematoma present indicator	Indicates presence of subdural hematoma	Yes; no; unknown	Supplemental—highly recommended
C13841	Subdural hematoma type	Indicates subdural hematoma type	Acute; subacute; chronic; lengthy; prolonged	Supplemental—highly recommended
C13845	Imaging shift present indicator	Indicates if any shift present	Yes; No; Unknown	Supplemental
C13846	Imaging shift type	Indicates shift type	Midline shift; septal shift; pineal shift	Supplemental
C13847	Imaging shift measurement	Indicates shift measurement		Supplemental
C13848	Hydrocephalus present indicator	Indicates if hydrocephalus is present	Yes; no; unknown	Supplemental—highly recommended
C13849	Bicaudate index score	Indicates Bicaudate index		Supplemental
C13850	Arteriovenous malformation present indicator	Indicates if arteriovenous malformation is present	Yes; No; Unknown	Supplemental—Highly Recommended
C13851	Arteriovenous malformation anatomic site	Specifies location of arteriovenous malformation		Supplemental—highly recommended
NEW	Barrow Neurological Institute (BNI) Scale—Aneurysmal subarachnoid hemorrhage thickness scale	BNI scale measures increasing SAH thickness on a quantitative scale and is used to predict the likelihood to develop symptomatic vasospasm	1 (no blood); 2 (SAH ≤ 5 mm); 3 (SAH 5 ≤ 10 mm); 4 (SAH 10 ≤ 15 mm); 5 (SAH > 15 mm)	Supplemental

ADC Apparent diffusion coefficient, ASL Arterial spin labeling, CBCT Cone-beam computed tomography, CDE Common data element, CE Contrast-enhanced, COW Circle of Willis, CT Computed tomography, DEXA Dual-energy x-ray absorptiometry, DIR Double inversion recovery, DTI Diffusion tensor imaging, DWI Diffusion weighted imaging, EEG Electroencephalography, FLAIR Fluid attenuated inversion recovery, FLASH Fast low angle shot imaging, fMRI Functional magnetic resonance imaging, FSE Fast spin echo, GRE Gradient echo imaging, ID Identification number, ISIS Image selected in vivo spectroscopy, IVH Intraventricular hemorrhage, MEG Magnetoencephalography, MPRAGE Magnetization prepared rapid gradient echo, MRA Magnetic resonance angiography, MR Magnetic resonance, MRI Magnetic resonance imaging, MRSI Magnetic resonance spectroscopic imaging, OCT Optical coherence tomography, PD Proton density, PET Positron emission tomography, PRESS Point resolved spectroscopy, PSIR Phase sensitive inversion recovery, PWI Perfusion weighted imaging, SA Subarachnoid, SAH Subarachnoid hemorrhage, SE Spin echo, SPACE Sampling perfection with application optimized contrast using different flip angle evolution, SPECT Single photon emission computed tomography, SPGR Spoiled gradient, STEAM Stimulated echo acquisition method, SWI Susceptibility weighted imaging, T1W T1 weighted, T2W T2 weighted, TOF Time-of-flight, TSE Turbo spin echo, VISTA Volume isotropic turbo spin echo acquisition

Table 2 CDEs—Angiography

CDE ID	CDE name	Definition	Permissible value	Unit	Classification
Vascular imaging					
C13750	Imaging study ID number	Unique identification number assigned to the study or assessment session	Alphanumeric		Supplemental—highly recommended
C02494	Imaging study date and time	Date (and time, if applicable and known), the radiologic study was obtained	Date Time	Month/Day/Year Hours:minutes	Supplemental—highly recommended
C18888	Imaging acquisition reason other text	The free-text field related to 'Imaging acquisition reason' specifying other text. Describes why the imaging study was performed	Alphanumeric		Supplemental—highly recommended
C13751	Imaging acquisition reason	Describes why the imaging study was performed	Diagnostic Post-treatment Monitoring		Supplemental—highly recommended
C13879 modified	Imaging modality vessel imaging angiography type	Indicates imaging modality for vessel imaging angiography	DSA MRA CTA CBCT		Core
C13880	Digital subtraction angiography (DSA) site of access anatomic site	The site of access for digital subtraction angiography (DSA), a type of fluoroscopy technique used in interventional radiology to clearly visualize blood vessels in a bony or dense soft tissue environment	Brachial Radial Femoral Other		Exploratory
C13881	Digital subtraction angiography (DSA) injection site anatomic site	The site of injection for digital subtraction angiography (DSA), a type of fluoroscopy technique used in interventional radiology to clearly visualize blood vessels in a bony or dense soft tissue environment	Arch Common carotid Internal carotid Vertebral Subclavian		Exploratory
C02411	Laterality type	Laterality type relative to the anatomic site of the body examined or affected			Supplemental
C13882	Magnetic resonance angiography type	The type as related to magnetic resonance angiography (MRA)	Alphanumeric		Supplemental—highly recommended
C13883	Computer tomography (CT) angiography type	The type of computer tomography angiography being performed	Head Neck Computer tomography venography (CTV)		Supplemental—highly recommended
C08254	Imaging visual analysis location performed type	Location where visual analysis of the imaging data is performed	Central Central read local site Local read Local report		Supplemental

Table 2 (continued)

CDE ID	CDE name	Definition	Permissible value	Unit	Classification
C18720	Imaging visual analysis location performed other text	The free-text field related to 'Imaging visual analysis location performed type' specifying other text. Location where visual analysis of the imaging data is performed	Alphanumeric		Supplemental
C08255	Imaging visual analysis blinded indicator	Indicator of whether the visual analysis was performed blinded to clinical data	Yes No Unknown		Supplemental
C10931	Imaging quality of images technically satisfactory indicator	Indicator of whether the quality of the images was technically satisfactory	Yes No Unknown Not applicable		Supplemental
C13884	Imaging vessel angiography arterial anatomic site	Indicates vessel imaging angiography arterial findings location	CCA origin CCA to bifurcation ICA at origin C1 cervical C2 petrous C3 lacerum C4 cavernous C5 clinoidal C6 ophthalmic to PCOM C6 PCOM to terminus A1 A2 M1 proximal to striate M1 distal to striate M2 single M2 multiple M3 single M3 multiple M4 single M4 multiple Vertebral origin Vertebral—cervical Vertebral—intracranial proximal to PICA Vertebral—distal to PICA Basilar—distal to AICA Basilar—mid Basilar—proximal to AICA PCOM P1 P2 P3 SCA AICA PICA		Core
C13885	Imaging vessel angiography arterial result	Indicates vessel imaging angiography arterial findings	Normal Occlusion Aneurysm Stenosis AVM Not visualized		Core
C13896	Imaging vessel angiography level of confidence status	Indicates vessel angiography level of confidence	Low Moderate High		Supplemental—highly recommended

Table 2 (continued)

CDE ID	CDE name	Definition	Permissible value	Unit	Classification
NEW	Imaging aneurysm shape type	Shape/pathology of aneurysm for each unruptured intracranial aneurysm	Saccular Fusiform Dissecting		Supplemental
NEW	Imaging vessel angiography aneurysm anatomic site	Anatomical site of aneurysm in vessel imaging angiography	C1 cervical C2 petrous C3 lacerum C4 cavernous C5 clinoidal C6 ophthalmic to PCOM C6 PCOM to terminus A1 A2 M1 proximal to striate M1 distal to striate M2 single M2 multiple M3 single M3 multiple M4 single M4 multiple Vertebral—intracranial proximal to PICA Vertebral—distal to PICA Basilar—distal to AICA Basilar—mid Basilar—proximal to AICA PCOM P1 P2 P3 SCA AICA PICA		Supplemental—highly recommended
NEW	Imaging aneurysm anatomic site	Aneurysm location	Cavernous Persistent trigeminal Medial paraclinoid Lateral paraclinoid Ophthalmic Superior hypophyseal Posterior communicating Anterior choroidal Internal carotid artery bifurcation Middle cerebral artery bifurcation Anterior communicating Pericallosal Posterior inferior cerebellar artery Superior cerebellar Basilar apex other		Supplemental—highly recommended
NEW	Imaging aneurysm dome measurement	Maximum diameter	Number	Millimeter	Supplemental—highly recommended
NEW	Imaging aneurysm neck measurement	Maximum diameter or width of aneurysm neck for each aneurysm	Number	Millimeter	Supplemental—highly recommended

Table 2 (continued)

CDE ID	CDE name	Definition	Permissible value	Unit	Classification
NEW	Imaging aneurysm lobe irregularity indicator	Presence of daughter lobes or aneurysm lobe irregularity	Yes No Unknown		Supplemental
NEW	Imaging unruptured intracranial aneurysm morphology type	Morphology type of aneurysm for each unruptured intracranial aneurysm	A: Regular B: Bleb C: Daughter-sac, multilobed aneurysm		Supplemental—highly recommended
NEW	Imaging aneurysm aspect ratio value	Maximum height divided by largest neck diameter for each aneurysm	Number	Millimeter	Supplemental—highly recommended
NEW	Imaging aneurysm thrombus indicator	Presence of mural thrombus or partial thrombosis in aneurysm	Yes No Unknown		Supplemental
C13885	Imaging vessel angiography arterial result	Indicates vessel imaging angiography arterial findings	Normal Occlusion Aneurysm Stenosis AVM Not visualized		Supplemental
C13886 modified	Imaging vessel angiography cause type	Indicates vessel imaging angiography cause	Atherosclerotic Embolic Other Unknown Vasospasm		Supplemental
C13887	Imaging vessel angiography symptomology type	Indicates vessel imaging angiography symptomology	Symptomatic Asymptomatic Indeterminate		Supplemental
C14006	Imaging stenosis percentage value	Indicates stenosis percentage value	Number	Percent	Supplemental
NEW	Imaging aneurysm 3D reconstruction indicator	Presence of 3D reconstruction of aneurysm	Yes No Unknown		Supplemental
Endovascular treatment					
NEW	Aneurysm wall apposition status	Wall apposition for stents or flow diverters	Good Poor Unknown		Supplemental
NEW	Aneurysm occlusion percentage value	Indicates the occlusion percentage of aneurysm	Number	Percent	Supplemental—highly recommended
NEW	Imaging aneurysm occlusion Raymond–Roy classification category	Raymond–Roy occlusion Classification of intracranial aneurysms	Complete occlusion Dog ear Residual neck Residual aneurysm		Supplemental—highly recommended
NEW	Imaging aneurysm parent branch vessel occlusion indicator	Indicates occlusion of parent vessel or branch vessel related to aneurysm	Yes No Unknown		Supplemental
Computational fluid dynamics: Volumetric factors					
NEW	Imaging aneurysm mean kinetic energy measurement	Indicates mean aneurysm kinetic energy measurement	Number		Exploratory
C13948	Imaging mean blood velocity measurement	Indicates mean velocity measurement	Number	cm/sec	Exploratory
NEW	Imaging aneurysm mean shear rate	Measure of the deformation of the fluid elements	Number		Exploratory
NEW	Imaging aneurysm mean vorticity measurement	Measure of the rotational velocity of fluid elements	Number		Exploratory

Table 2 (continued)

CDE ID	CDE name	Definition	Permissible value	Unit	Classification
NEW	Imaging aneurysm mean viscous dissipation measurement	Indicates mean aneurysm viscous dissipation	Number		Exploratory
NEW	Imaging aneurysm vortex coreline length measurement	Indicates vortex coreline length, a measure of complexity of the intra-aneurysmal flow pattern	Number	Centimeter	Exploratory
Computational fluid dynamics: Surface factors					
NEW	Aneurysm mean wall shear stress measurement	Indicates the mean aneurysm wall shear stress	Number	dyne/cm ²	Supplemental
NEW	Aneurysm maximum wall shear stress measurement	Indicates the maximum aneurysm wall shear stress	Number	dyne/cm ²	Supplemental
NEW	Aneurysm minimum wall shear stress measurement	Indicates the minimum aneurysm wall shear stress	Number	dyne/cm ²	Supplemental
NEW	Aneurysm shear concentration index measurement	measures the degree of concentration of the wall shear stress distribution	Number		Exploratory
NEW	Aneurysm low shear area percentage value	Indicates the percentage of the aneurysm area under low wall shear stress relative to the parent vasculature	Number	Percent	Exploratory
NEW	Aneurysm oscillatory shear index measurement	Indicates the mean aneurysm oscillatory shear stress	Number		Exploratory
Computational fluid dynamics: Hemodynamic factors					
NEW	Aneurysm mean inflow rate measurement	Indicates mean aneurysm inflow rate	Number	ml/sec	Exploratory
NEW	Aneurysm inflow concentration index measurement	Measures the degree of concentration of the flow stream entering the aneurysm, percentage of the flow rate of the parent artery that enters the aneurysm divided by the percentage of the aneurysm ostium area that corresponds to positive inflow velocity	Number		Exploratory

ACOM Anterior communicating artery, AICA Anterior inferior cerebellar artery, AVM Arteriovenous malformation, CBCT Cone-beam computed tomography, CCA Common carotid artery, CDE Common data element, CTA Computed tomography angiography, DSA Digital subtraction angiography, ICA Internal carotid artery, ID Identification number, MRA Magnetic resonance angiography, PCOM Posterior communicating artery, PICA Posterior inferior cerebellar artery, SCA Superior cerebellar artery

Perfusion Imaging

For 'Perfusion imaging,' we compiled 20 CDEs. Of these 14 CDEs reused and six CDEs were newly created. Specific parameters included mean transit time, cerebral blood flow, cerebral blood volume, time to peak, and time to maximum of the residue function. Other important Supplemental (but not highly recommended CDEs) included processing methods (deconvolution or not) and specific thresholds chosen to define a perfusion abnormality. None was classified as core.

The five Supplemental—Highly Recommended CDEs were:

- Imaging study ID number
- Imaging study date and time
- Acquisition reason
- Acquisition reason other text
- Imaging slice thickness value

Table 3 CDEs—Perfusion imaging

CDE ID	CDE name	Definition	Permissible value	Classification
C13750	Imaging study ID number	Unique identification number assigned to the study or assessment session	Alphanumeric	Supplemental—highly recommended
C02494	Imaging study date and time	Date (and time, if applicable and known), the radiologic study was obtained		Supplemental—highly recommended
C18888	Imaging acquisition reason other text	The free-text field related to 'Imaging acquisition reason' specifying other text. Describes why the imaging study was performed		Supplemental—highly recommended
C13751	Imaging acquisition reason	Describes why the imaging study was performed	Diagnostic; post-treatment; monitoring	Supplemental—highly recommended
C18701	Imaging modality other text	The free-text field related to 'Imaging modality type' specifying other text. Type of radiologic study performed on the participant/subject		Supplemental
C02437 modified	Imaging modality type	Type of radiologic study performed on the participant/subject	Non-contrast CT; contrast CT; post-contrast CT; CT-angiography; CT perfusion; CBCT; PET; SPECT; MRI; non-contrast MRI; contrast MRI; MRI angiography; MRI perfusion; X-ray angiography; OCT; microscopy; MEG; EEG; MEG; DEXA; ultrasound	Supplemental
NEW	Imaging CT slice value	Value for the number of slices of the CT	64; 128; 256; 320; other, specify	Supplemental
C18718	Imaging scanner strength other text	The free-text field related to 'Imaging scanner strength value' specifying other text. Value, in Tesla (T), of the scanner's magnetic field strength used for the scan being reported		Supplemental
C02495	Imaging scanner strength value	Value, in Tesla (T), of the scanner's magnetic field strength used for the scan being reported	1.5; 3.0; 4.0; 7.0	Supplemental
C08244	Imaging slice thickness value	Value of the thickness of the slice measured in millimeters		Supplemental—highly recommended
C18720	Imaging visual analysis location performed other text	The free-text field related to 'Imaging visual analysis location performed type' specifying other text. Location where visual analysis of the imaging data is performed		Supplemental
C08254	Imaging visual analysis location performed type	Location where visual analysis of the imaging data is performed	Central; central read; local-site; local read; local report	Supplemental
C08255	Imaging visual analysis blinded indicator	Indicator of whether the visual analysis is performed blinded to clinical data	Yes; no; unknown	Supplemental
C10931	Imaging quality of images technically satisfactory indicator	Indicator of whether the quality of the images was technically satisfactory	Yes; no; unknown; not applicable	Supplemental
NEW	Perfusion imaging modality type	Type of radiologic perfusion study	CT; MR	Supplemental
NEW	Perfusion imaging calculation method type	Indicates method used for perfusion calculation	No deconvolution; deconvolution without delay correction; deconvolution with delay correction	Supplemental

Table 3 (continued)

CDE ID	CDE name	Definition	Permissible value	Classification
NEW	Perfusion imaging parameter abnormality type	Indicates perfusion parameter used to delineate abnormality	Mean transit time lesion volume; time to peak lesion volume; cerebral blood volume (CBV) defect volume; time-to-max (Tmax) lesion volume; cerebral blood flow (CBF) lesion volume	Supplemental
NEW	Perfusion imaging parameter threshold result	Indicates threshold value for abnormality		Supplemental
NEW	Perfusion imaging parameter volume measurement	Indicates volume of perfusion abnormality		Supplemental
C13875	Imaging perfusion computed tomography based identification perfusion defect result	Result of perfusion CT (PCT) based identification of perfusion defect value of abnormality		Supplemental

CBCT Cone-beam computed tomography, *CDE* Common data element, *CT* Computed tomography, *DEXA* Dual-energy x-ray absorptiometry, *EEG* Electroencephalography, *ID* Identification number, *MEG* Magnetoencephalography, *MR* Magnetic resonance, *MRI* Magnetic resonance imaging, *OCT* Optical coherence tomography, *PET* Positron emission tomography, *SPECT* Single photon emission computed tomography

The remaining 15 Supplemental elements are listed in Table 3.

Transcranial Doppler

There are 55 CDEs in the category ‘Transcranial doppler,’ all of them were reutilized from NINDS CDEs. None was classified as core.

The four Supplemental—Highly Recommended CDEs were:

- Imaging study ID number
- Imaging study date and time
- Acquisition reason
- Acquisition reason other text

We classified the remaining 51 CDEs as Exploratory (Table 4).

Discussion

Imaging plays a key role in clinical research related to UIA and SAH. Therefore, clear, consistent definitions to describe different imaging modalities, techniques and findings are critical for communicating and comparing data between studies. This paper describes the recommendations, and the process by which they were developed, from a group of experienced clinical investigators for Imaging CDEs for UIA and SAH. The WG was able to incorporate many ($n=100$) existing CDEs that were developed for ischemic stroke by the NINDS CDE WGs. An additional 36 CDEs were newly defined.

The WG created four main categories to encompass these CDEs. These categories can be thought of as menus and mirror the categories created for the NINDS CDEs. Their purpose is to aid investigators searching for

relevant CDEs when designing their studies and developing case report forms. Many of these CDEs and their categories are pulled directly from the NINDS stroke CDEs. Parenchymal Imaging was used to capture findings from cross-sectional imaging (CT and MR), and to characterize hemorrhage (including the subarachnoid and intraventricular spaces). Some of these CDEs, such as the modified Fisher scale, have substantial validation as predictors of outcome [6]. The category of Angiography was created to encompass vascular imaging, endovascular treatment, and CFD parameters. Perfusion imaging was developed for capturing these parameters which are largely relevant to SAH-induced vasospasm. Finally, the group created a separate category for transcranial Doppler, as it did not fit neatly into the other categories.

Two new CDEs were created within Parenchymal Imaging. The first defines the number of CT slices for the CT scanner (e.g., 16, 64, 128 etc.). The second was to add the Barrow Neurological Institute Scale for definition of aneurysmal SAH thickness as a Supplemental CDE [8]. The Fisher, modified Fisher, Hijdra, and Graeb scales already existed within the NINDS Stroke CDEs and were pulled over [4–6, 9].

Twenty-seven new CDEs were developed for angiography. Many related to the emerging data for aneurysm morphology (such as aspect ratio), angiographic results after treatment [7], and the use of CFD [10, 11]. Many of the morphologic and CFD factors are associated with a history of rupture and may have a role in the prediction of future rupture. Prospective studies will be needed to establish these as risk factors. Use of these CDEs will help with comparisons between these future studies and to drive standardization for these definitions. This is particularly a problem for CFD parameters which can vary greatly between investigators [12, 13].

Table 4 CDEs—Transcranial Doppler

CDE ID	CDE name	Definition	Permissible value	Classification
C13750	Imaging study ID number	Unique identification number assigned to the study or assessment session		Supplemental—highly recommended
C02494	Imaging study date and time	Date (and time, if applicable and known), the radiologic study was obtained		Supplemental—highly recommended
C18888	Imaging acquisition reason other text	The free-text field related to 'Imaging acquisition reason' specifying other text. Describes why the imaging study was performed		Supplemental—highly recommended
C13751	Imaging acquisition reason	Describes why the imaging study was performed	Diagnostic; post-treatment; monitoring	Supplemental—highly recommended
C13899	Imaging probe type text	The text describing the type of imaging probe		Exploratory
C13900	Imaging probe frequency	Indicates imaging probe frequency (Hz)		Exploratory
C13901	Imaging patient type	Indicates imaging patient type	Asymptomatic; acute stroke; chronic stroke; brain edema; vasospasm	Exploratory
C13902	Imaging acute stroke study type	Indicates imaging acute stroke study type	Initial; follow-up 1; follow-up 2	Exploratory
C13903	Imaging interpretation site indicator	Indicates imaging interpretation site		Exploratory
C13904	Imaging interpretation offsite media type	Indicates imaging offsite media type	Video; print; digital	Exploratory
C10570	Imaging contrast agent used indicator	Indicator as to whether an imaging contrast agent was used for the scan as part of diffusion tensor imaging (DTI)	Yes; no; unknown; not applicable	Exploratory
C18693	Imaging contrast agent method other text	The free-text field related to 'Imaging contrast agent method type' specifying other text. Indicates imaging contrast agent method of administration		Exploratory
C13905	Imaging contrast agent method type	Indicates imaging contrast agent method of administration	Bolus; infusion; other, specify	Exploratory
C18720	Imaging visual analysis location performed other text	The free-text field related to 'Imaging visual analysis location performed type' specifying other text. Location where visual analysis of the imaging data is performed		Supplemental
C08254	Imaging visual analysis location performed type	Location where visual analysis of the imaging data is performed	Central; central read; local-site; local read; local report	Supplemental
C08255	Imaging visual analysis blinded indicator	Indicator of whether the visual analysis was performed blinded to clinical data	Yes; no; unknown	Supplemental
C10931	Imaging quality of images technically satisfactory indicator	Indicator of whether the quality of the images were technically satisfactory	Yes; no; unknown; not applicable	Supplemental
C14008	Imaging window quality category	Indicates window quality category	Temporal; posterior; orbital	Exploratory
C14009	Imaging window quality result	Indicates window quality result for all categories	Fair; excellent; poor	Exploratory
C13942	Imaging vessel category	Indicates vessel category	M1; insular M2; A1; internal carotid artery (ICA); P1; P2; EC ICA; siphon; vertebral; basilar; ophthalmic	Exploratory
C02411	Laterality type	Laterality type relative to the anatomic site of the body examined or affected		Exploratory
C14056	Imaging depth measurement	The depth measurement (mm) of imaging		Exploratory

Table 4 (continued)

CDE ID	CDE name	Definition	Permissible value	Classification
C13947	Imaging peak velocity measurement	Indicates peak velocity measurement (cm/s)		Exploratory
C13948	Imaging mean blood velocity measurement	Indicates mean velocity measurement (cm/s) of blood		Exploratory
C14007	Imaging Transcranial Doppler (TCD) findings result type	Indicates Transcranial Doppler (TCD) findings	Reversed diastolic flow; systolic spike; no signals; reduced upstroke/pulsatility index (PI)	Exploratory
C13949	Imaging flow/probe direction type	Indicates flow/probe direction	Toward; away from	Exploratory
C14037	Imaging power M mode left middle cerebral artery result	Indicates power M mode for left middle cerebral artery (MCA) result	Absent; high resistance; low resistance	Exploratory
C14038	Imaging power M mode right middle cerebral artery result	Indicates power M mode for right middle cerebral artery (MCA) result	Absent; high resistance; low resistance	Exploratory
C14034	Vasomotor response (VMR) vessel anatomic site	Indicates vasomotor response (VMR) vessel type	M1; A1; P1; siphon; ophthalmic; vertebral; basilar; middle cerebral artery; other, specify	Exploratory
C18903	Vasomotor response (VMR) vessel anatomic other text	The free-text field related to 'Vasomotor response (VMR) vessel anatomic site' specifying other text. Indicates vasomotor response (VMR) vessel type		Exploratory
C14035	VMR response result	Indicates vasomotor response (VMR) response result	Abnormal; normal	Exploratory
C14036	Breath-holding index result	Indicates Breath-holding index (BHI) result		Exploratory
C14000	Extracranial stenosis present indicator	Indicates presence of extracranial stenosis	Yes; no; unknown	Exploratory
C14001	Extracranial stenosis type	Indicates extracranial stenosis type	Collateral; reduced upstroke; reduced pulsatility index (PI); VMR; reduced velocity	Exploratory
C14002	Extracranial stenosis collateral artery anatomic site	The site of parallel arteries having extracranial stenosis	Ophthalmic artery; anterior cerebral artery; vertebral artery	Exploratory
C14011	Intracranial stenosis present indicator	Indicates presence of intracranial stenosis	Yes; no; unknown	Exploratory
C14010	Intracranial stenosis collateral vessel anatomic site	Indicates intracranial stenosis collateral vessel(s)	Internal carotid artery; basilar; middle cerebral artery; anterior cerebral artery; vertebral artery; posterior cerebral artery; other, specify	Exploratory
C18900	Intracranial stenosis collateral vessel anatomic other text	The free-text field related to 'Intracranial stenosis collateral vessel anatomic site' specifying other text. Indicates intracranial stenosis collateral vessel(s)		Exploratory
C14006	Imaging stenosis percentage value	Indicates stenosis percentage value		Exploratory
C14012	Intracranial stenosis peak systolic velocity (PSV) criterion result	Indicates intracranial stenosis peak systolic velocity (PSV) criterion		Exploratory
C14013	Intracranial stenosis mean velocity criterion value	Indicates intracranial stenosis mean velocity criterion		Exploratory
C14014	Intracranial stenosis other criteria result	Other criteria for intracranial stenosis		Exploratory
C14028	Vasospasm present indicator	Indicates presence of vasospasm	Yes; no; unknown	Exploratory
C14031	Vasospasm status	Indicates vasospasm result	Abnormal; normal	Exploratory
C14032	Vasospasm severity grade	Indicates severity of vasospasm	Mild; moderate; severe	Exploratory

Table 4 (continued)

CDE ID	CDE name	Definition	Permissible value	Classification
C18902	Vasospasm vessel anatomic other text	The free-text field related to 'Vasospasm vessel anatomic site' specifying other text. Indicates vasospasm vessel(s)		Exploratory
C14033	Vasospasm vessel anatomic site	Indicates vasospasm vessel(s)	Internal carotid artery; basilar; middle cerebral artery; anterior cerebral artery; vertebral artery; other, specify	Exploratory
C14024	Vasospasm criterion value	Indicates vasospasm criterion value		Exploratory
C14025	Vasospasm Lindegaard ratio value	Indicates vasospasm Lindegaard ratio result		Exploratory
C14029	Vasospasm posterior ratio result	Indicates vasospasm posterior ratio result		Exploratory
C14026	Intracranial pressure imaging result	Indicates intracranial pressure (ICP) imaging result		Exploratory
C14030	Vasospasm resistive index indicator	Indicates vasospasm resistive index (RI)	Yes; no; unknown	Exploratory
C14027	Intracranial pressure (ICP) other measurement text	Indicates other method of measuring intracranial pressure (ICP)		Exploratory
C01559	Arterial partial pressure carbon dioxide value	Measurement of how much carbon dioxide is dissolved in the arterial blood and how well carbon dioxide can move out of the body (PaCO ₂)		Exploratory
C14052	Hemoglobin measurement	The measurement for hemoglobin		Exploratory

CDE Common data element, EC Extracranial, ICA Internal carotid artery, ID Identification number, M mode Motion mode, VMRVasomotor response

Perfusion imaging in SAH-induced vasospasm is also an emerging area in need of validation and standardization for both prediction and diagnosis [14]. Most perfusion imaging CDEs were taken from the existing stroke CDE menu, and six new ones were created, which are related to calculation methodology and definition of thresholds for abnormalities. Finally, all 55 CDEs for transcranial Doppler were carried forward from the stroke CDEs. No new ones were created

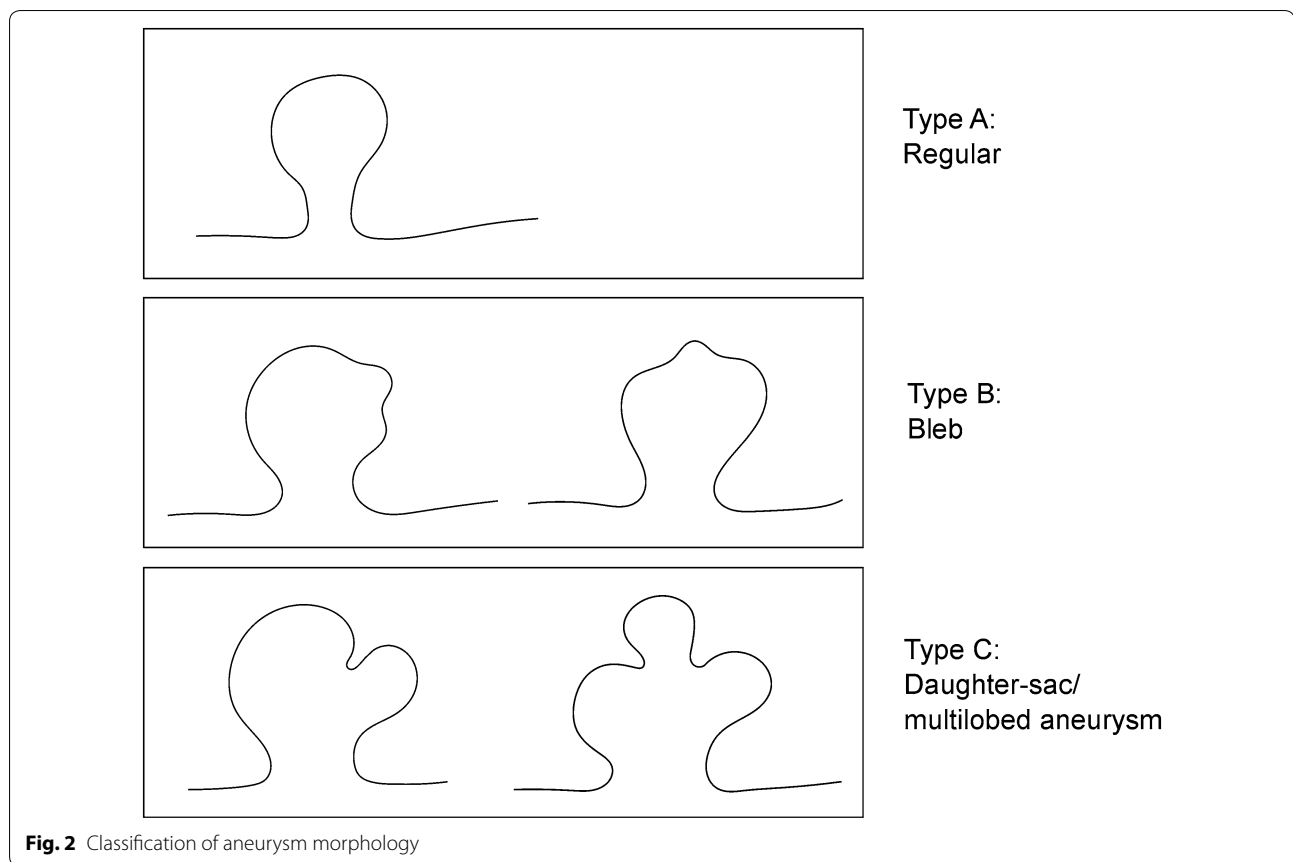
Limitations

The proposed CDEs have limitations. The WG identified and defined numerous data elements for imaging studies and data in the setting of SAH, based on existing and/or most commonly used definitions. A balance was needed between very detailed definitions, which would decrease the feasibility of using these CDEs, and broad definitions, which are easier to use in clinical practice but may provide fewer scientific details. Thus, many of these definitions and their scientific implications lack prospective validation. Further, several CDEs were reused and in some cases adapted from established CDEs on other entities.

A consensus approach was used to define and rank the individual importance of data elements. Other potentially relevant data elements suggested could not be included at present because of the lack of validated imaging modalities or grading scales for such imaging outcomes. Additionally, together with the UIA Subcommittee, a novel classification system for aneurysm morphology (Fig. 2) was established and agreed on, for which there was no established data from the previous cohort or case-control studies to support this exact classification. However, since three-dimensional aneurysm morphologies are difficult to measure or to describe in standardized manner, a two-dimensional classification was agreed upon as a basis for further research. Lastly, the proposed CDEs on imaging in the setting of SAH will need to be adapted or even expanded in the future, once novel data or imaging techniques become available.

Next Steps/Future Work

Future clinical studies will be needed to test and validate the relative importance of many of the SAH imaging CDEs described above. In addition, these CDEs will require updating in the future as further information is gained.



Conclusions

A total of 136 CDEs were defined and categorized, 100 of them were derived from previously established CDEs on ischemic stroke and 36 which were newly created for the UIA and SAH CDE project. These imaging CDEs in the setting of UIAs and SAH will serve as a basis to aggregate imaging data, and help to harmonize data across studies. However, the CDEs remain to be validated, adapted and updated in the future based on novel data to optimize existing CDEs and establish new CDEs.

Author details

¹ Department of Neurosurgery, Medical Faculty Mannheim, University Hospital Mannheim, University of Heidelberg, Theodor-Kutzer-Ufer 1-3, 68167 Mannheim, Germany. ² Department of Radiology, Stanford University, Palo Alto, CA, USA. ³ Departments of Radiology and Neurological Surgery, Columbia University, New York, NY, USA. ⁴ Departments of Radiology and Neurosurgery, Mayo Clinic, Rochester, MN, USA. ⁵ Klinik Hirslanden, Zurich, Switzerland. ⁶ Division of Neuroradiology, University of Toronto, Toronto, ON, Canada. ⁷ Department of Radiology, Mayo Clinic, Rochester, MN, USA. ⁸ Brain Center Rudolf Magnus, Department of Neurology and Neurosurgery and Center of Excellence for Rehabilitation Medicine, University Medical Center Utrecht, Utrecht University, Utrecht, The Netherlands. ⁹ Departments of Radiology and Neurology, University of Iowa, Iowa City, IA, USA.

Acknowledgements

The views expressed here are those of the authors and do not represent those of the National Institutes of Health (NIH), the National Institute of Neurological Disorders and Stroke (NINDS) or the US Government. Logistical support for this project was provided in part through NIH Contract HHSN271201200034C, the Intramural Research Program of the NIH, NLM, The Neurocritical Care Society and the CHI Baylor St Luke's Medical Center in Houston, TX. The development of the NINDS SAH CDEs was made possible thanks to the great investment of time and effort of WG members and the members of the NINDS CDE Project and NLM CDE project teams participating from 2015–2017.

UIA and SAH WORKING GROUP MEMBERS

Steering Committee

Jose I Suarez, MD, FNCS, FANA, Johns Hopkins University School of Medicine, Baltimore, MD, co-Chair; R Loch Macdonald, MD, PhD, University of Toronto, Toronto, ON, Canada, co-Chair; Sepideh Amin-Hanjani, MD—University of Illinois at Chicago, Chicago, IL; Robert D. Brown, Jr., MD, MPH—Mayo Clinic, Rochester, MN; Airtón Leonardo de Oliveira Manoel, MD, PhD—University of Toronto, Toronto, Ontario, Canada; Colin P Derdeyn, MD, FACR—University of Iowa, Carver College of Medicine, Iowa City, IA; Nima Etminan, MD—University Hospital Mannheim, Mannheim, Germany; Emanuela Keller, MD—University of Zurich, Zurich, Switzerland; Peter D. LeRoux, MD, FACS—Main Line Health, Wynnewood, PA; Stephan Mayer, MD—Henry Ford Hospital, Detroit, MI; Akio Morita, MD, PhD—Nippon Medical School, Tokyo, Japan; Gabriel Rinkel, MD—University Medical Center, Utrecht, The Netherlands; Daniel Rufennacht, MD—Klinik Hirslanden, Zurich, Switzerland; Martin N. Stienen, MD, FEBNS—University of Zurich, Zurich, Switzerland; James Torner, MSc, PhD—University of Iowa, Iowa City, IA; Mervyn D.I. Vergouwen, MD, PhD—University Medical Center, Utrecht, The Netherlands; George K. C. Wong, MD—Chinese University of Hong Kong, Shatin, Hong Kong.

Subject Characteristics Working Group

Robert D. Brown, Jr., MD, MPH—Mayo Clinic, Rochester, MN, co-Chair; Akio Morita, MD, PhD—Nippon Medical School, Tokyo, Japan, co-Chair; Philippe Bijlenga, MD, PhD, Geneva University Hospital, Geneva, Switzerland (Superuser); Nerissa Ko, MD; Cameron G McDougall, MD; J Mocco, MS, MD; Yuuichi Murayama, MD; Marieke J H Werner, MD, PhD.

Assessments and Examinations Working Group

Stephan Mayer, MD—Henry Ford Hospital, Detroit, MI, co-Chair; Jose I Suarez, MD, FNCS, FANA, The Johns Hopkins University School of Medicine, Baltimore, MD, co-Chair; Rahul Damani, MD, MPH, Baylor College of Medicine, Houston, TX (Superuser); Joseph Broderick, MD; Raj Dhar, MD, FRCPC; Edward C Jauch, MD, MS, FACEP, FAHA; Peter J Kirkpatrick; Renee H Martin, PhD; J Mocco, MS, MD; Susanne Muehlschlegel, MD, MPH; Tatsushi Mutoh, MD, DVM, PhD; Paul Nyquist, MD, MPH; Daiwai Olson, RN, PhD; Jorge H Mejia-Mantilla, MD, MSc.

Hospital Course and Acute Therapies Working Group

Sepideh Amin-Hanjani, MD—University of Illinois at Chicago, Chicago, IL, co-Chair; Airton Leonardo de Oliveira Manoel, MD, PhD—University of Toronto, Toronto, Ontario, Canada, co-Chair (Superuser); Mathieu van der Jagt, MD, PhD, Erasmus Medical Center, Rotterdam, The Netherlands (Superuser); Nicholas Bambakidis, MD; Gretchen Brophy, PharmD, BCPS, FCCP, FCCM, FNCS; Ketan Bulsara, MD; Jan Claassen, MD, PhD; E Sander Connolly, MD, FACS; S Alan Hoffer, MD; Brian L Hoh, MD, FACS; Robert G Holloway, MD, MPH; Adam Kelly, MD; Stephan Mayer, MD; Peter Nakaji, MD; Alejandro Rabinstein, MD; Jose I Suarez, MD, FNCS, FANA; Peter Vajkoczy, MD; Mervyn D. I. Vergouwen, MD, PhD; Henry Woo, MD; Gregory J Zipfel, MD.

Biospecimens and Biomarkers Working Group

Emanuela Keller, MD—University of Zurich, Zurich, Switzerland, co-Chair (Superuser); R Loch Macdonald, MD, PhD, University of Toronto, Toronto, ON, Canada, co-Chair; Sherry Chou, MD, MMSc; Sylvain Doré, PhD, FAHA; Aaron S Dumont, MD; Murat Gunel, MD, FACS, FAHA; Hidetoshi Kasuya, MD; Alexander Roederer, PhD; Ynte Ruijgrok, MD; Paul M Vespa, MD, FCCM, FAAN, FANA, FNCS; Asita Simone Sarrafzadeh-Khorrasani, PhD.

Imaging Working Group

Colin P Derdeyn, MD, FACR—University of Iowa, Carver College of Medicine, Iowa City, IA, co-Chair; Nima Etminan, MD University Hospital Mannheim, Mannheim, Germany, co-Chair; Katharina A. M. Hackenberg, MD, University Hospital Mannheim, Mannheim, Germany (Superuser); John Huston, III, MD; Timo Krings, MD, PhD, FRCPC; Giuseppe Lanzino, MD; Philip M Meyers, MD, FACR, FSIR, FAHA; Gabriel Rinkel, MD; Daniel Rufennacht, MD; Max Wintermark, MD.

Long-Term Therapies Working Group

James Torner, MSc, PhD—University of Iowa, Iowa City, IA, co-Chair (Superuser); George K. C. Wong, MD—Chinese University of Hong Kong, Shatin, Hong Kong, co-Chair (Superuser); Joseph Broderick, MD; Janis Daly, PhD, MS; Christopher Ogilvy, MD; Denise H Rhoney, PharmD, FCCP, FCCM, FNCS; YB Roos, PhD; Adnan Siddiqui, MD, PhD, FAHA.

Unruptured Intracranial Aneurysms Working Group

Nima Etminan, MD—University Hospital Mannheim, Mannheim, Germany, co-Chair; Gabriel Rinkel, MD—University Medical Center, Utrecht, The Netherlands, co-Chair; Katharina A. M. Hackenberg, MD, University Hospital Mannheim, Mannheim, Germany (Superuser); Ale Algra, MD, FAHA; Juhanna Frösen, MD; David Hasan, MD; Seppo Juvela, MD, PhD; David J Langer, MD; Philip M Meyers, MD, FACR, FSIR, FAHA; Akio Morita, MD, PhD; Rustam Al-Shahi Salman, MA, PhD, FRCPC.

Outcomes and Endpoints Working Group

Martin N. Stienen, MD, FEBNS—University of Zurich, Zurich, Switzerland, co-Chair (Superuser); Mervyn D.I. Vergouwen, MD, PhD—University Medical Center, Utrecht, The Netherlands, co-Chair; Daniel Hanggi, MD; R Loch Macdonald, MD, PhD; Tom Schweizer, PhD; Johanna Visser-Meily, MD, PhD.

National Library of Medicine CDE Team

Liz Amos, MLIS, National Information Center on Health Services Research and Health Care Technology, National Library of Medicine; Christophe Ludet, MS, National Library of Medicine, Bethesda, MD.

NINDS CDE Team

Claudia Moy, PhD, NINDS, Bethesda, MD, Joanne Odenkirchen, MPH, NINDS, Bethesda, MD, Sherita Ala'i, MS, The Emmes Corporation, Rockville, MD, Joy Esterlitz, MS, The Emmes Corporation, Rockville, MD, Kristen Joseph, MA, The Emmes Corporation, Rockville, MD, Muniza Sheikh, MS, MBA, The Emmes Corporation, Rockville, MD.

Author contributions

KAMH, NE, and CD were involved in protocol development and manuscript writing/editing; MW, PMM, GL, DR, TK, JH 3rd, and GR contributed to manuscript writing/editing. The corresponding author confirms that authorship requirements have been met, the final manuscript was approved by ALL authors, and that this manuscript has not been published elsewhere and is not under consideration by another journal. The UIA and SAH CDEs project adhered to ethical guidelines.

Conflict of interest

Dr Hackenberg has nothing to disclose. Dr Etminan has nothing to disclose. Dr Wintermark has nothing to disclose. Dr Meyers has nothing to disclose. Dr Lanzino has nothing to disclose. Dr Rüfenacht has nothing to disclose. Dr Krings has nothing to disclose. Dr Huston has nothing to disclose. Dr Rinkel has nothing to disclose. Dr Derdeyn reports personal fees from Penumbra, Inc, grants from Siemens, Inc, outside of the submitted work.

Publisher's Note

Springer Nature remains neutral with regard to jurisdictional claims in published maps and institutional affiliations.

Published online: 21 May 2019

References

- Grinnon ST, Miller K, Marler JR, Lu Y, Stout A, Odenkirchen J, et al. National institute of neurological disorders and stroke common data element project—approach and methods. *Clin Trials (Lond, Engl)*. 2012;9:322–9.
- Saver JL, Warach S, Janis S, Odenkirchen J, Becker K, Benavente O, et al. Standardizing the structure of stroke clinical and epidemiologic research data: the national institute of neurological disorders and stroke (ninds) stroke common data element (cde) project. *Stroke J Cereb Circ*. 2012;43:967–73.
- Damani R, Mayer S, Dhar R, Martin RH, Nyquist P, Olson DM, et al. Common data element for unruptured intracranial aneurysm and subarachnoid hemorrhage: recommendations from assessments and clinical examination workgroup/subcommittee. *Neurocrit Care*. 2019. <https://doi.org/10.1007/s12028-019-00736-1>.
- Graeb DA, Robertson WD, Lapointe JS, Nugent RA, Harrison PB. Computed tomographic diagnosis of intraventricular hemorrhage. Etiology and prognosis. *Radiology*. 1982;143:91–6.
- Fisher CM, Kistler JP, Davis JM. Relation of cerebral vasospasm to subarachnoid hemorrhage visualized by computerized tomographic scanning. *Neurosurgery*. 1980;6:1–9.
- Frontera JA, Claassen J, Schmidt JM, Wartenberg KE, Temes R, Connolly ES Jr, et al. Prediction of symptomatic vasospasm after subarachnoid hemorrhage: the modified fisher scale. *Neurosurgery*. 2006;59:21–7.
- Roy D, Milot G, Raymond J. Endovascular treatment of unruptured aneurysms. *Stroke J Cereb Circ*. 2001;32:1998–2004.
- Wilson DA, Nakaji P, Abula AA, Uschold TD, Fusco DJ, Oppenlander ME, et al. A simple and quantitative method to predict symptomatic vasospasm after subarachnoid hemorrhage based on computed tomography: beyond the fisher scale. *Neurosurgery*. 2012;71:869–75.

9. Hijdra A, van Gijn J, Nagelkerke NJ, Vermeulen M, van Crevel H. Prediction of delayed cerebral ischemia, rebleeding, and outcome after aneurysmal subarachnoid hemorrhage. *Stroke J Cereb Circ.* 1988;19:1250–6.
10. Ujiie H, Tachibana H, Hiramatsu O, Hazel AL, Matsumoto T, Ogasawara Y, et al. Effects of size and shape (aspect ratio) on the hemodynamics of saccular aneurysms: a possible index for surgical treatment of intracranial aneurysms. *Neurosurgery.* 1999;45:119–29.
11. Liang L, Steinman DA, Brina O, Chnafa C, Cancelliere NM, Pereira VM. Towards the clinical utility of cfd for assessment of intracranial aneurysm rupture—a systematic review and novel parameter-ranking tool. *J Neurointerv Surg.* 2019;11:153–8.
12. Kallmes DF. Point: cfd—computational fluid dynamics or confounding factor dissemination. *AJNR Am J Neuroradiol.* 2012;33:395–6.
13. Valen-Sendstad K, Bergersen AW, Shimogonya Y, Goubergrits L, Bruening J, Pallares J, et al. Real-world variability in the prediction of intracranial aneurysm wall shear stress: the 2015 international aneurysm cfd challenge. *Cardiovasc Eng Technol.* 2018;9:544–64.
14. Cremers CH, van der Schaaf IC, Wensink E, Greving JP, Rinkel GJ, Velthuis BK, et al. Ct perfusion and delayed cerebral ischemia in aneurysmal subarachnoid hemorrhage: a systematic review and meta-analysis. *J Cereb Blood Flow Metab.* 2014;34:200–7.